



Narrative Review Cardiac Critical Care

Regional Anesthesia in Cardiac Surgery and Critical Care

Poonam Malhotra Kapoor¹

¹Department of Cardiac Anesthesia and Critical Care, CNC, All India Institute of Medical Sciences, New Delhi, India.

***Corresponding author:**

Poonam Malhotra Kapoor,
Department of Cardiac
Anesthesia and Critical Care,
CNC, All India Institute of
Medical Sciences, New Delhi,
India.

docpoonamaiims@gmail.com

Received : 28 April 2023

Accepted : 02 May 2023

Published : 30 May 2023

DOI

10.25259/JCCC_26_2023

Quick Response Code:



INTRODUCTION

In spite of being in an era of minimally invasive cardiac surgery, median sternotomy remains a norm in most cardiac surgery centers. Post-operative pain that ensues subsequently, needs effective management with drugs and regional techniques. Regional anesthesia is defined as any technique to induce the absence of sensation in part of the body. Regional anesthesia needs to be given in a dedicated center, with expert hands only. There are advantages and disadvantages of using Regional Anaesthesia (RA) techniques [Table 1]. Regional anesthesia's chief disadvantages include hypotension, risk of toxicity to the patient, and use of heparin mobility in a cardiac surgical patient, which prevents the giving of neuraxial blocks, in that it may cause the morbid complication of epidural hematoma. Despite the availability today of different types of regional anesthesia techniques accessible to us, there is a conundrum in use of regional anesthesia in cardiac surgery, due to the use of this anticoagulant heparin. Employing a local regional block, in and around the thorax, serves to circumvent and alleviate this pain.

DIFFERENT REGIONAL ANAESTHESIA TECHNIQUES

Types of regional anesthesia include: Topical, intravenous (Bier's) block, peripheral nerve blocks like femoral, pectoralis minor and major blocks, plexus: Brachial, lumbar, and Neuro-axial block epidural, spinal and combined blocks.

As Magoon *et al.* point out in this issues of the journal, that in the cardiac surgical patient today, there is a trend to move towards both minimally invasive cardiac surgical techniques and fast tracking with enhanced recovery, yet most open heart surgeries employ a median sternotomy incision, making post-operative pain a actuality.^[1]

Many regional blocks, guided by ultrasound use have recently been proposed by intensivists, of which the pecto-intercostal (PIFB) and transversus thoracic muscle plane block, hold a lot of potential [Table 2] as does the Erector spinae Block.^[2-4]

EFFECTS OF ULTRASOUND GUIDED REGIONAL ANESTHESIA IN CARDIAC SURGERY TODAY IS A MODERN TECHNIQUE TO ALLEVIATE PAIN

Many systematic reviews and Meta-analysis, exist on use of RA in general surgery, but there are few-only in cardiac surgery and evolving.^[3]

This is an open-access article distributed under the terms of the Creative Commons Attribution-Non Commercial-Share Alike 4.0 License, which allows others to remix, transform, and build upon the work non-commercially, as long as the author is credited and the new creations are licensed under the identical terms.

©2023 Published by Scientific Scholar on behalf of Journal of Cardiac Critical Care TSS

Dost *et al.* effectively used in their meta-analysis, the primary outcome as opioid consumption during the first 24 h after surgery. The secondary outcomes were pain after extubating at 12 and 24 h, post-operative nausea and vomiting, extubating time, intensive care unit discharge time, and length of hospital stay. 15 studies with 849 patients were included. The regional anesthesia techniques included PIFB, transversus thoracic muscle plane block, erector spinae plane (ESP) block, and pectoralis nerve block I. All the regional anesthesia techniques included significantly reduced post-operative opioid consumption at 24 h, expressed as morphine milligram equivalents (MME). The ESP block was the most effective treatment (-22.93 MME [-34.29; -11.56]). In this meta-analysis, they concluded that fascial plane blocks were better than placebo when evaluation was done at 24 h.^[5] A brief review of each block is described below: [Table 3].

Table 1: Advantages and disadvantages of regional anesthesia.

Advantages	Disadvantages
<ul style="list-style-type: none"> • Cheap, Versatile; safe, with high patient satisfaction • High patient satisfaction • Maintain patent airway • Decreased blood loss • Selective muscle relaxation • Decreased incidence of DVT and PE • Early mobility • Decreased opioid consumption • Analgesia • Decreased anesthesia drug requirements • Era of ERAS and TAVR RA is in 	<ul style="list-style-type: none"> • Hypotension • Risk of toxicity • Many patients prefer to be asleep • Skills are required • Patient can talk • Patient anxiety • Not reliable for surgery >2 h
DVT: Deep venous thrombosis, PE: Pulmonary embolism, ERAS: Enhanced recovery after surgery, TAVR: Transcatheter aortic valve replacement, RA: Regional anesthesia	

SONOANATOMY AND BLOCK TECHNIQUE OF PECSI AND PECS II REGIONAL BLOCK

PECS I and II blocks are typically performed under ultrasound guidance using an in-plane aseptic technique with the patient in a supine position. A 12 to 15-MHz linear ultrasound probe is placed at a midclavicular line below the clavicle, and the subclavian vessels are identified. The probe is moved infero laterally to the level of the third rib. With a slight medial tilt, the three layers of muscles are identified: Pectoralis major, pectoralis minor, and serratus anterior. When performing both blocks simultaneously, single puncture site can be used to preserve near-field imaging with deposition of the LA between the layers of the serratus anterior and pectoralis minor (PECS II) [Figure 1].

PECTO-INTERCOSTAL FASCIAL (PIF) AND TRANSVERSE THORACIC MUSCLE PLANE (TTMP) BLOCKS

A deeper version of the PIF, namely, a TTMP block, with the injection between the internal intercostal and transverse thoracic muscles was described as well. However, the transverse thoracic muscle is a very thin structure lying posterior to the sternum and can be difficult to appreciate with ultrasound. It provides analgesia to the anterior lateral and posterior chest wall.

SERRATUS ANTERIOR PLANE BLOCK IN CARDIAC SURGERY

The reported spread of the SAP block involves approximate levels between T2 and T9 including anterior, lateral, and posterior chest wall, but sparing the mid chest. It is important to emphasize that the spread is primarily influenced by the volume of LA injected as well as injection site deep or superficial to the SAM. It is suggested that achieving a spread

Table 2: Various blocks used for cardiac surgery.

Name of the block	Target nerve	Target plane	Area covered
PECS 1 and 2	PECS 1 lateral and medial pectoral nerve PECS 2 intercostal nerve (T2-T6) long thoracic	Between pectoralis major and minor between pectorals minor and serratus anterior	Anterior chest wall anterior and lateral part and axilla
ESB	Dorsal and ventral rami	Deep to erector spinae muscle at the level of T6 transverse process	Anterior and posterior chest wall, axilla and medical aspect of upper arm
PIFB	Anterior cutaneous branches of intercostal nerve	Between pectoralis major and external intercostal muscle, on lateral side of sternal margin	Medical part of chest wall
TTP block	Multiple anterior cutaneous branches of thoracic 2-6 segments	Between transverse thoracic muscle and intercostal muscle	Medical part of chest wall including internal mammary area
PECS: Pectoral nerve block, ESB: Erector spinae block, PIFB: Pectointercostal fascial plane block, TTP: Transverse thoracic muscle plane			

Table 3: Chest wall fascial plane blocks for specific cardiac surgical approaches.

Surgical approach	Block options	UL/BL
Sternotomy	PIF or ESP	BL
Minimally invasive right anterolateral thoracotomy	PECS I, PECS II and PIF or ESP	UL left
Minimally invasive right thoracotomy (robotic)	PECS II and SAP or ESP	UL Left
Trans apical TAVR	SAP or ESP	UL left

PIF: Pectointercostal fascial, TAVR: Transcatheter aortic valve replacement, PECS: Pectoral nerve block, SAP: Serratus anterior plane, ESP: Erector spinae plane

from approximate dermatomal levels T1–T8 requires the LA volume more than 40 mL [Figure 2].

ERECTOR SPINE PLANE BLOCK (ESP)

Initially described for the treatment of chronic thoracic neuropathic pain, the ESP block has recently seen utilized for acute post-operative analgesia involving chest, thoracic, cardiac, and abdominal surgeries. Referred to as a “paravertebral block by proxy,” the ESP block deposits LA solutions ventral to the erector spine muscle along 5–9 thoracic levels within the costotransverse foramen region preventing nociception along both the ventral and dorsal rami of spinal nerves [Figure 3].

PARAVERTEBRAL BLOCK

This block is used for thoracotomy, minimally invasive, and robotic surgeries and for midline approach bilaterally. Single-shot multi or single-level block using a catheter can be performed. Ultrasound guidance increases success rates.

LOCAL ANAESTHETIC (LAS) USED FOR FASCIAL PLANE CHEST WALL BLOCKS

Bupivacaine and ropivacaine are the most commonly used LAS reported in the literature with concentrations varying from 0.0625% to 0.5% and volumes injected ranging between 10 and 40 mL depending on the site of injection. Use of many adjuvants to prolong block duration including opioids, α 2-adrenoceptor agonists, and steroids have been described in recent literature.^[6]

LOCAL ANAESTHETIC DIFFUSION THEORY

Even though an injection site in the PECS II block is more lateral than in the parasternal zone, local anesthetics tend to extend in all directions of the fascial plane, reaching the anterior intercostal cutaneous branches medially.^[7]

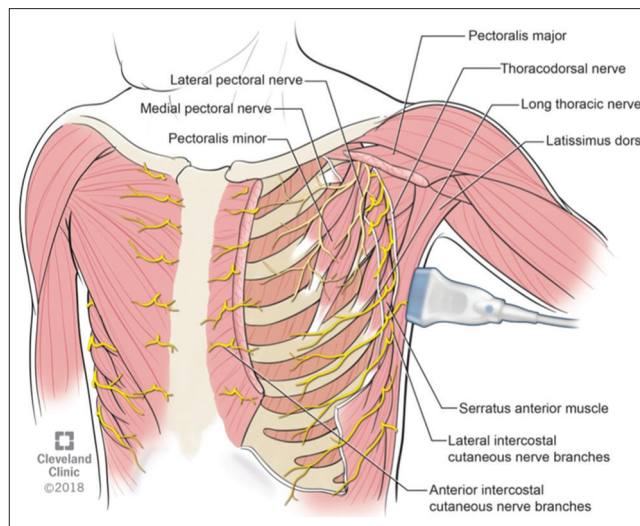


Figure 1: Anterolateral chest wall anatomy muscles and nerves ideal for PECS I and PECS II. PECS: Pectoral nerve block.

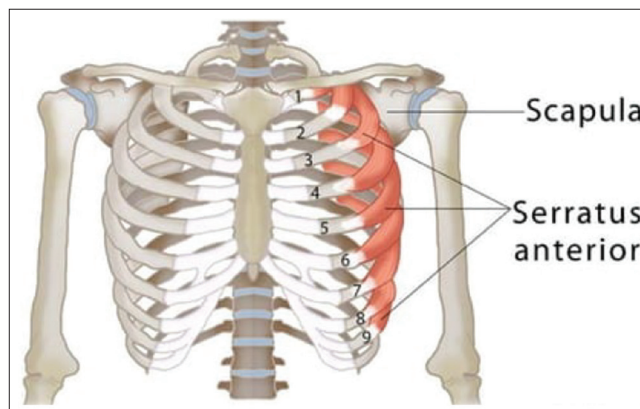


Figure 2: Serratus anterior.

WHICH BLOCK IS BEST SUITED IN CARDIAC SURGICAL PATIENTS?

Farouk Kamal *et al.* have also concluded recently that PECS block is an efficient technique that can be implemented as an integral part of fast-track cardiac surgery.^[7] In the case of sternotomy, it was evident that bilateral PECS II block was more effective than systemic analgesia alone, even though the anatomical explanation is unknown. The anterior branches of the intercostal nerves are distantly away to be blocked by PECS block. Nonetheless, they may induce analgesia by lowering pectoral or intercostal muscular spasms. The same conflict is present with ESP block, despite being commonly used in cardiac surgery, its mechanism of action is still undetermined.^[8]

In this issue of JCCC TSS, do read interesting articles on different regional blocks by Singh *et al.*; Magoon *et al.*; Das *et al.*; and Jose *et al.* are included in the point of care

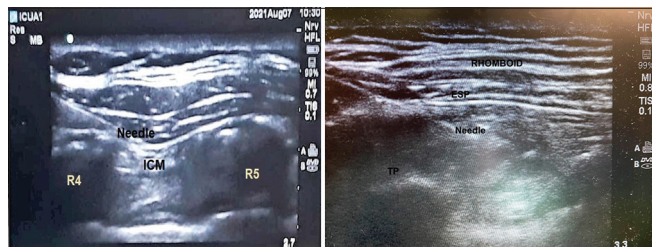


Figure 3: Ultrasound planes seen in Sonosite machine for pain control following coronary artery bypass graft (CABG).

technique section. Cardiac surgical patients enjoy reading their experience in this new era for early mobility and cardiac safety of the patients. A simple femoral nerve block for embolectomy obviates giving a general anesthesia drug and brings greater patient satisfaction. Enjoy reading this issue on other articles as well and give us your feedback.

CONCLUSION

Knowledge and skills in regional analgesia have become very important for a cardiothoracic anesthesiologist in today's era of minimally invasive cardiac surgery as it strives toward faster functional recovery and discharge. Future research should focus on establishing dosing regimens for specific fascial plane blocks in cardiac surgery, with efficacy and safety in mind. The mechanisms of novel blocks such as ESP, PIF and adductor canal block using liposomal bupivacaine with adjuvants is an exciting era forwards with RA use in cardiac surgery.

REFERENCES

1. Magoon R, Jose J, Kaushal B. Pecto-intercostal fascial block in the cardiac surgical patient. *J Card Crit Care* 2023;7:100-1.
2. Jose J, Magoon R, Kaushal B. Rectus sheath block in cardiac surgery. *J Card Crit Care* 2023;7:104-5.
3. Singh R, Das SN. Femoral nerve block for emergency femoral artery saddle embolectomy. *J Card Crit Care* 2023;7:111-2.
4. Singh R, Singh S, Choudhary A, Sharan S, Hote MP, Kapoor PM. Erector spinae block. *J Cardiac Crit Care TSS* 2021;5:154-6.
5. Dost B, De Cassai A, Balzani E, Tulgar S, Ahiskalioglu A. Effects of ultrasound-guided regional anesthesia in cardiac surgery: A systematic review and network meta-analysis. *BMC Anesthesiol* 2022;22:409.
6. Chakravarthy M, Jawali V, Patil TA, Jayaprakash K, Kolar S, Joseph G, *et al.* Conscious cardiac surgery with cardiopulmonary bypass using thoracic epidural anesthesia without endotracheal general anesthesia. *J Cardiothorac Vasc Anesth* 2005;19:300-5.
7. Kamal F, El-Rahman AA, Hassan RM, Helmy AF. Efficacy of bilateral PECS II block in postoperative analgesia for ultrafast track pediatric cardiac anesthesia. *Egypt J Anaesth* 2022;38:150-7.
8. Kapoor PM, Choudhury M, Kakani M. Thoracic epidural anesthesia in cardiac surgery-current standing. *Ann Cardiac Anaesth* 2009;12:167-8.

How to cite this article: Poonam MK. Regional anesthesia in cardiac surgery and critical care. *J Card Crit Care TSS* 2023;7:75-8.