



Case Report

Dextrocardia with Atrial Septal Defect: Interesting Echocardiography Images

Ajmer Singh¹, Ravina Mukati¹

¹Department of Cardiac Anaesthesia, Institute of critical Care and Anaesthesiology, Medanta The Medicity, Gurugram, Haryana, India.

*Corresponding author:

Ajmer Singh,
Department of Cardiac
Anaesthesia, Medanta the
Medicity, Gurugram, Haryana,
India.

ajmersingh@yahoo.com

Received: 11 June 2024
Accepted: 05 November 2024
Epub Ahead of Print: 09 December 2024
Published: 23 January 2025

DOI

[10.25259/JCCC_30_2024](https://doi.org/10.25259/JCCC_30_2024)

Quick Response Code:



Videos available on:
[https://doi.org/10.25259/
JCCC_30_2024](https://doi.org/10.25259/JCCC_30_2024)

ABSTRACT

Approximately 3 to 5% of patients with congenital cardiac disease have dextrocardia with situs inversus. During the transesophageal echocardiographic evaluation of these patients, modifications of multiplane angles and manipulations of the probe are required to obtain desired echocardiographic views compared to patients with normal hearts. The case described here had mirror-image dextrocardia with atrial septal defect. We describe interesting echocardiographic images which were acquired using different angles and probe manipulations.

Keywords: Dextrocardia, Atrial septal defect, Transesophageal echocardiography

INTRODUCTION

Dextrocardia can present either as an isolated anomaly with normal viscerotrial relationship (situs solitus), along with some of the organs on the contralateral side (situs inversus or SI) or with every vital organ of the chest and abdomen on the other side of the body. The latter condition is termed SI totalis or mirror image dextrocardia (MID). The specific etiology of dextrocardia is unknown, but there is evidence of inheritance as an autosomal recessive trait or through mutations in a gene through the X-chromosome.^[1] Electrocardiogram, chest radiograph, echocardiogram, computed tomographic scan, and magnetic resonance imaging are helpful for the diagnosis of dextrocardia. An abdominal ultrasound scan can confirm SI totalis by revealing the mirror-image positioning of the organs of the abdomen.^[1] There is limited literature on the transesophageal echocardiography (TEE) imaging of patients with dextrocardia. Modifications of imaging angles and manipulations of the TEE probe are required to acquire standard TEE images.

CASE REPORT

A man aged 39 years, a known case of atrial septal defect (ASD), with worsening dyspnea, was admitted for closure of the ASD. On physical checkup, the point of maximal impulse was perceptible in the right fifth intercostal space and the liver dullness was present in the left subcostal region. Electrocardiogram showed right axis deviation with global negativity (P-wave inversion with negative QRS complexes in lead I and lead aVL), positive P-waves and upright QRS complexes in lead aVR, and progressively decreasing amplitude of R-waves with dominant S-waves from lead V₁ to lead V₆ [Figure 1]. The chest X-ray showed dextrocardia with rightward

This is an open-access article distributed under the terms of the Creative Commons Attribution-Non Commercial-Share Alike 4.0 License, which allows others to remix, transform, and build upon the work non-commercially, as long as the author is credited and the new creations are licensed under the identical terms.

©2025 Published by Scientific Scholar on behalf of Journal of Cardiac Critical Care TSS

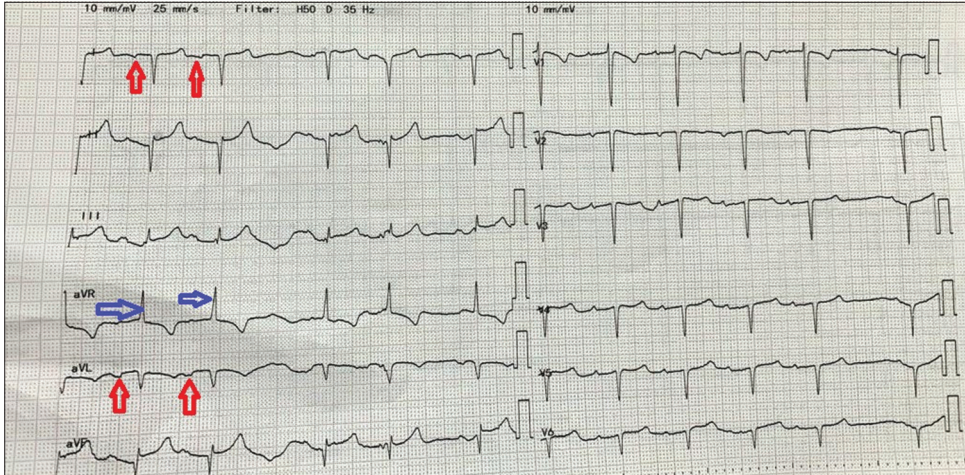


Figure 1: Electrocardiogram showing inverted P-waves and negative QRS in lead I and lead aVL (red arrows), positive P-waves and upright QRS complexes in lead aVR (blue arrows), and poor progression of R-waves in precordial leads.

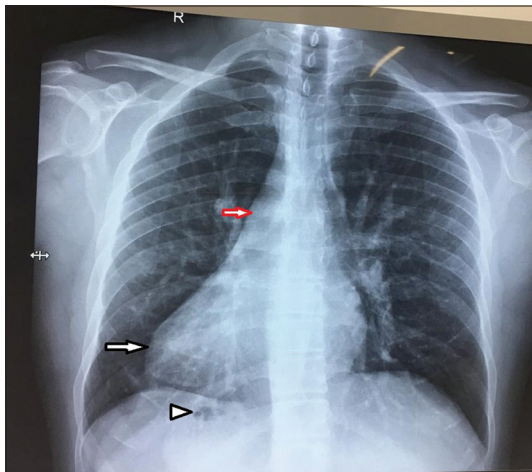


Figure 2: Chest radiograph showing dextrocardia (black arrow), right aortic arch (red arrow), and gastric bubble on the right side (arrow head).

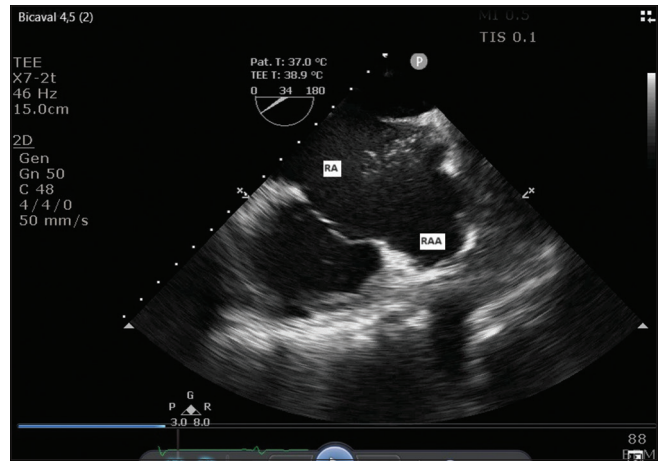


Figure 3: Midesophageal modified bicaval view showing right atrium with agitated saline appearing in it through superior vena cava, and broad-based right atrial appendage.

orientation of the apex of the heart, right-sided aortic arch, and stomach bubble on the right side [Figure 2]. A two-dimensional transthoracic echocardiography showed SI with dextrocardia, normal systemic venous drainage, normal pulmonary venous drainage, atrioventricular and ventriculoarterial concordance, dilated right atrium, dilated right ventricle, a 2.7 cm ASD secundum with a left to right shunt, deficient inferior vena cava and aortic rims, normal right ventricular function, mild tricuspid regurgitation, and right-sided aortic arch.

Intraoperative monitoring consisted of standard cardiac monitoring, including TEE. It confirmed the findings of pre-operative echocardiography. Some of the important TEE views acquired are described here. The right atrium was identified by its broad-based appendage and by

the administration of saline into the right hand and its appearance in the right atrium [Figure 3]. The mid esophageal four-chamber (ME 4C) view acquired at a transducer angle of zero degree showed the right heart chambers on the right side of the display, which is contrary to the TEE view seen in a normally positioned heart [Figure 4 and Video 1]. The presence of the moderator band and the caudal placement of the right atrioventricular valve compared to the left atrioventricular valve helped in the identification of the right ventricle. At a transducer angle of about 140°, a mirror-image ME 4C view was acquired with the right-heart chambers on the left side of the display and the left-sided chambers on the right side as seen in a normally positioned heart [Figure 5]. The aortic arch was viewed in the upper esophageal (UE) aortic arch long-axis (LAX) view. To obtain this view, from the ME

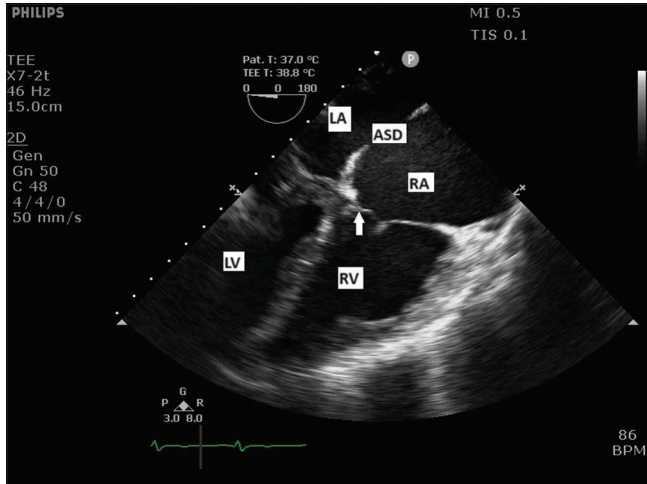


Figure 4: Midesophageal four-chamber view showing left atrium (LA) and left ventricle (LV) on the left side of display. Right atrium (RA), right ventricle (RV), and apically placed tricuspid valve (arrow) are seen on the right side. ASD: Atrial septal defect.

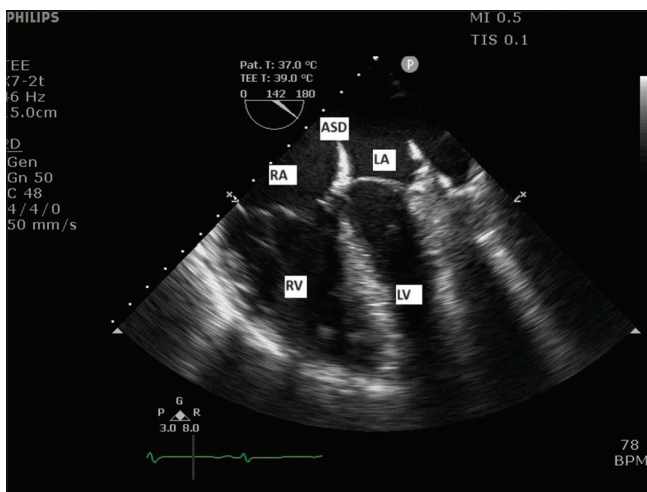
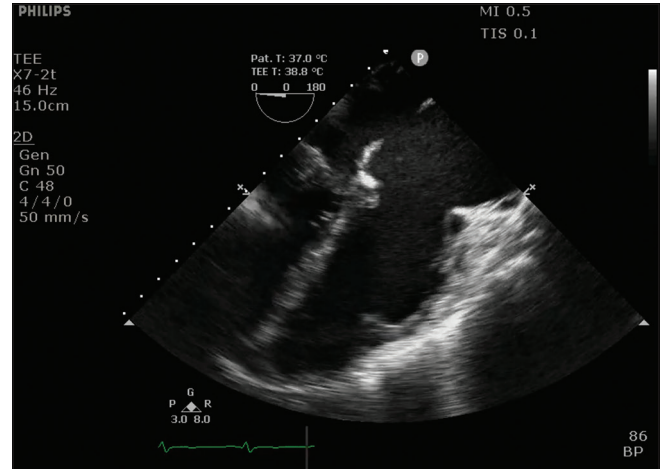


Figure 5: Mirror-image mid-esophageal four-chamber view showing left atrium (LA), left ventricle (LV) on the right side and right atrium (RA), and right ventricle (RV) on the left side of the display. ASD: Atrial septal defect.

4C view, the TEE probe was rotated to the right instead of the left to focus the descending aorta in the center of the image. The TEE probe was then withdrawn until the aorta appeared oval-shaped. The TEE probe was rotated a little to the left to image the proximal aortic arch. The right aortic arch was confirmed as it was seen coursing from the right to the left. The proximal aortic arch was seen in the far field, and the distal arch was visualized in the near field [Figure 6]. A normal aortic arch (left-sided aortic arch) is seen coursing the display from the left in the far field (proximal arch) to the right in the near field (distal arch). By slight advancement and retroflexion of the TEE probe



Video 1: Midesophageal four-chamber view showing right atrium, right ventricle on the right side, and left atrium, left ventricle on the left side. Atrial septal defect is also seen.

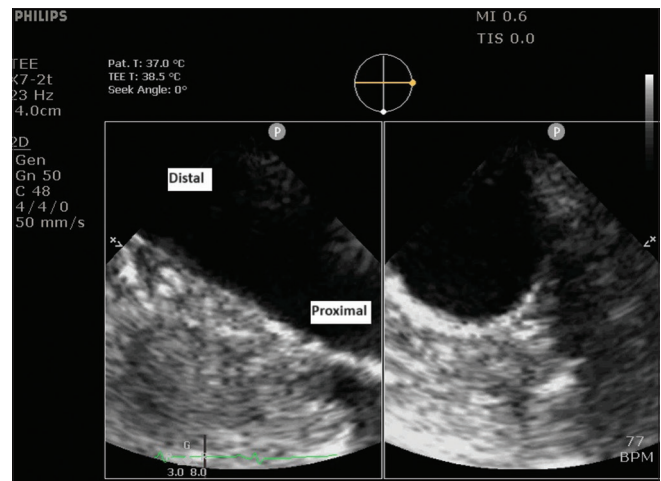


Figure 6: Upper esophageal aortic arch long-axis X-plane view showing right aortic arch traversing from the right in the far-field (proximal) to the left in the near-field (distal arch).

from the ME 4C view, the LAX view of the coronary sinus was seen coursing from the right side to the left side, which in a normal course traverses from the left to the right side [Figure 7]. The left upper pulmonary vein was viewed in the UE view at an angle of 140° by rotating the TEE probe clockwise instead of a normal counterclockwise rotation [Figure 8]. Mid esophageal (ME) right ventricle inflow-outflow view, normally found at an angle of 50°–70°, was acquired at a multiplane angle of 140° [Figure 9]. An absent aortic rim was also seen in this view [Figure 9 and Video 2]. ME modified bicaval view was acquired at a multiplane angle of 34° instead of a normal 50°–70° angle by rotating the TEE probe a little counterclockwise from the ME right ventricle inflow-outflow view [Figure 10]. ME LAX axis view was acquired at a multiplane angle of 36° instead of a

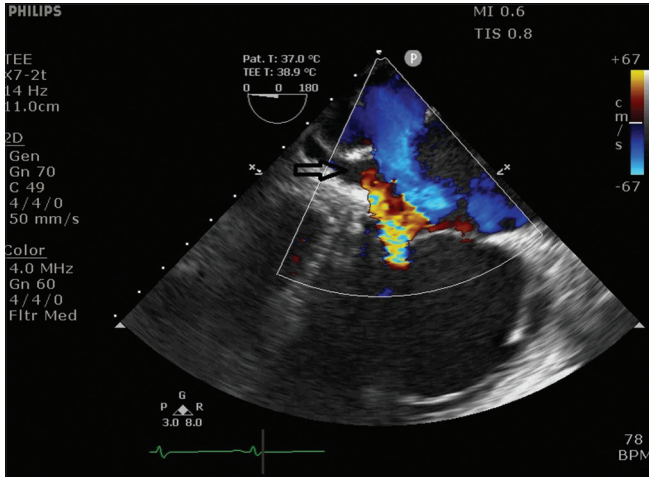


Figure 7: Midesophageal four-chamber view, showing long axis of coronary sinus (arrow) coursing from the right side to the left side.

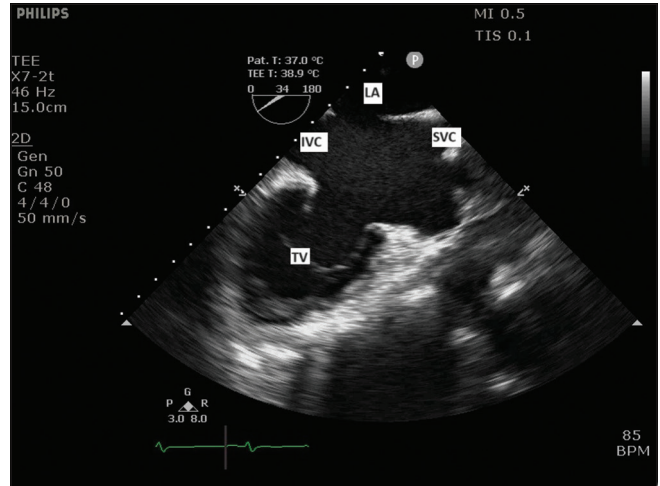


Figure 10: Midesophageal modified bicaval view showing superior vena cava (SVC), inferior vena cava (IVC), tricuspid valve (TV), and left atrium (LA).

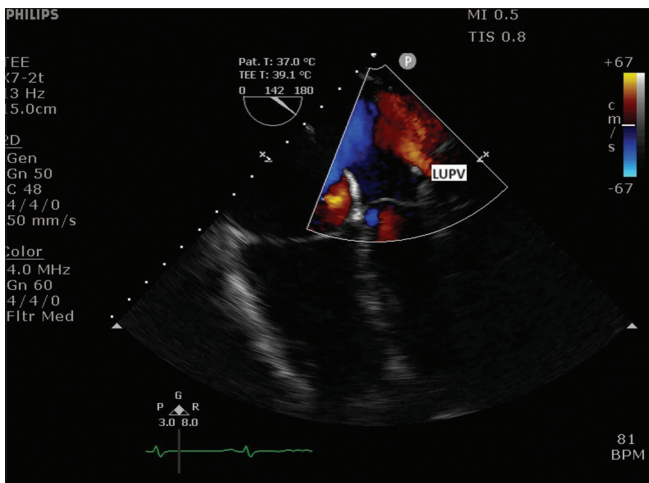


Figure 8: Upper esophageal view showing left upper pulmonary vein (LUPV).

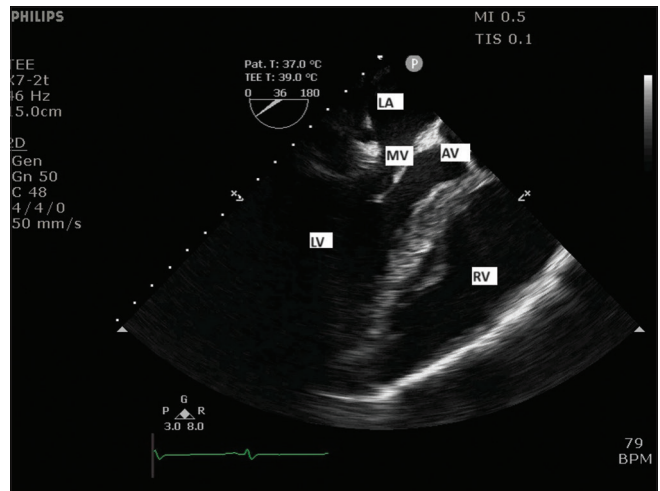


Figure 11: Midesophageal long-axis view (at 36° angle) showing left atrium (LA), mitral valve (MV), left ventricle (LV), aortic valve (AV), and right ventricle (RV).

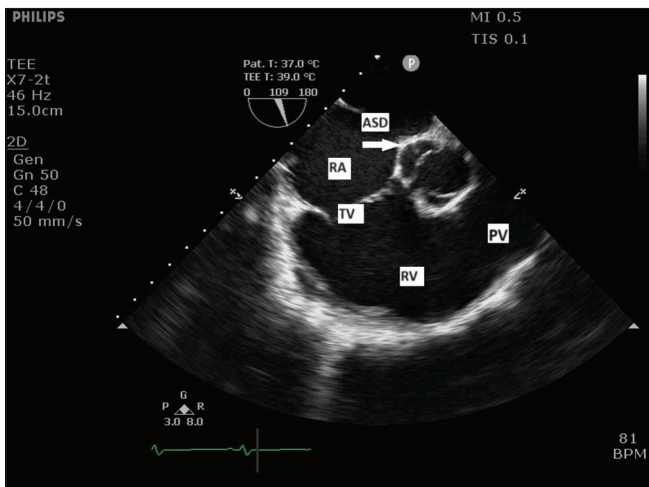
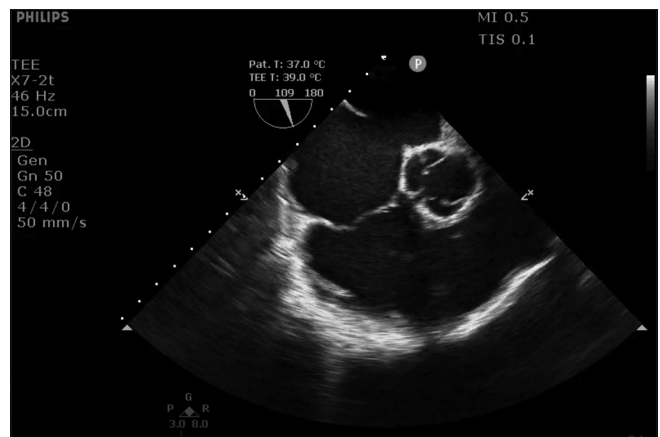


Figure 9: Midesophageal right ventricle inflow-outflow view showing right atrium (RA), tricuspid valve (TV), right ventricle (RV), and pulmonary valve (PV). Atrial septal defect (ASD) with deficient aortic rim is also seen (arrow).



Video 2: Midesophageal right ventricle inflow-outflow view showing deficient aortic rim.

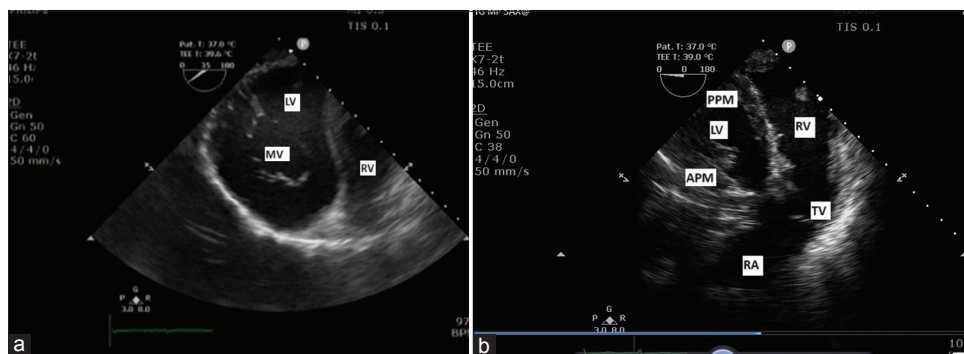


Figure 12: (a) Transgastric (TG) basal short-axis view showing mitral valve (MV), left ventricle (LV) on the left side, and right ventricle (RV) on the right side. (b) TG midpapillary short-axis view showing anterior papillary muscle (APM), posterior papillary muscle (PPM), LV on the left side with right atrium (RA), tricuspid valve (TV), and RV on the right side.

normal 120° – 140° angle [Figure 11]. Transgastric (TG) basal short-axis (SAX) view showed a “fish-mouth” appearance of the left atrioventricular valve. The left ventricle was viewed on the left side of the display, and the right ventricle was visualized on the right side of the display which is opposite of the TEE view obtained in a normal heart [Figure 12a]. TG mid papillary SAX view showed anterior and posterior papillary muscles and left ventricle on the left side of the display. Furthermore, the right ventricle, right atrium, and right atrioventricular valve were seen on the right side of the display [Figure 12b], which is again contrary to the TEE findings in a normally positioned heart.

DISCUSSION

Dextrocardia is an inborn cardiac abnormality in which the heart is positioned in the right chest cavity with the rightward orientation of the base-to-apex axis. The distinct anatomical features of SI totalis include: (i) Three lobes in the left lung and two lobes in the right lung, (ii) the left-sided larger lobe of the liver, (iii) the right-sided stomach and spleen, and (iv) the morphologic left atrium to the right of the morphologic right atrium. In type I dextrocardia (MID), as described here, the right heart chambers are positioned to the left of and anterior to the left heart chambers. Dextrocardia with SI is present in about 0.01% of the population. In addition, about 3–5% of the cases of congenital heart disorders have dextrocardia with SI.^[2] SI with dextrocardia is less commonly seen with other cardiac abnormalities, which can be a transposition of great arteries, ventricular septal defect, or double outlet right ventricle. The literature is very scarce on the TEE assessment of patients with dextrocardia. For TEE evaluation during a planned surgical procedure in these patients, a systematic approach with modifications of multiplane angles should be adhered to to define the anatomy and associated abnormalities. Raut *et al.* have described some of the TEE views and various multiplane

angles and probe manipulations required to acquire these views.^[3] Most ME views in MID can be obtained when the transducer angle is at 180° minus the recommended angle for the standard view.^[4]

Determination of situs is an essential step in patients with congenital heart disorders due to the variable anatomy of systemic and pulmonary veins. On TEE evaluation, the morphological right atrium is identified by broad-based right atrial appendage. The left atrial appendage, in contrast, bears a long, narrow, and finger-like appearance. After the determination of the situs, the next step is the evaluation of the aortic arch by TEE. Right-sided aortic arch is observed in 80% of the individuals with dextrocardia and SI.^[5] The aortic arch is seen in the UE LAX and SAX views. The right-sided aortic arch is seen traversing the display from the right to the left. The proximal arch is seen in the far field, and the distal arch is visualized in the near field which is converse to the left-sided aortic arch.^[6] Commonly used TEE views in the intraoperative period, such as the ME 4C view, aortic valve SAX view, right ventricle inflow-outflow view, TG basal SAX view, and TG mid-papillary SAX view, appear as mirror images of the normal heart. TEE images acquired at a 120° angle, such as ME LAX view, are obtained at 30° – 40° in dextrocardia patients, which reconfirms the “ 180° minus the prescribed angle” theory suggested by Kumar *et al.*^[4] If the echocardiographer prefers to avoid confusion regarding multiplane angles, most of these views can be acquired through right-left inversion option available in most echocardiography machines.^[7]

CONCLUSION

Many inborn cardiac or non-cardiac abnormalities can be seen associated with dextrocardia, but SI with dextrocardia is less commonly seen with other cardiac abnormalities. For

the acquisition of TEE images in patients with this anomaly, different multiplane angles and probe maneuvers are required to obtain standard views.

Ethical approval: Institutional Review Board approval is not required.

Declaration of patient consent: The authors certify that they have obtained all appropriate patient consent.

Financial support and sponsorship: Nil.

Conflicts of interest: There are no conflicts of interest.

Use of artificial intelligence (AI)-assisted technology for manuscript preparation: The authors confirm that there was no use of artificial intelligence (AI)-assisted technology for assisting in the writing or editing of the manuscript and no images were manipulated using AI.

REFERENCES

1. Deshimo G, Abebe H, Damtew G, Demeke E, Feleke S. A Case Report of Dextrocardia with Situs Inversus: A Rare Condition and Its Clinical Importance. *Case Rep Med* 2024;2024:2435938.
2. Ellis K, Fleming RJ, Griffiths SP, Jameson G. New Concepts in

- Dextrocardia: Angiographic Considerations. *AJR* 1966;97:295-313.
3. Raut MS, Maheshwari A, Shad S, Rachna G. How Standard Transesophageal Echocardiography Views Change with Dextrocardia. *Ann Card Anaesth* 2013;16:218-20.
4. Kumar MG, Ganesan R, Puri GD. Transesophageal Echocardiographic Diagnosis and Imaging of Cardiac Situs and Malposition. *J Perioper Echocardiogr* 2017;5:64-9.
5. Bae SB, Kang EJ, Choo KS, Lee J, Kim SH, Lim KJ, *et al.* Aortic Arch Variants and Anomalies: Embryology, Imaging Findings, and Clinical Considerations. *J Cardiovasc Imaging* 2022;30:231-62.
6. Jerath A, Roscoe A, Vegas A. Normal Upper Esophageal Transesophageal Echocardiography Views. *Anesth Analg* 2012;115:507-10.
7. Nakasone C, Kanamoto M, Tatsuishi W, Abe T, Saito S. Anesthetic Management of a Patient with Situs Inversus Totalis Undergoing Coronary Artery Bypass Grafting Surgery: A Case Report. *JA Clin Rep* 2021;7:28.

How to cite this article: Singh A, Mukati R. Dextrocardia with Atrial Septal Defect: Interesting Echocardiography Images. *J Card Crit Care TSS*. 2025;9:55-60. doi: 10.25259/JCCC_30_2024