




Point of Technique *Cardiac Critical Care*

## Step-by-Step Atraumatic Technique of Harvesting of the Radial Artery using Harmonic Scalpel: A Video Presentation

Ujjwal K. Chowdhury<sup>1</sup> , Niwin George<sup>2</sup>, B. Kanmaniyan<sup>2</sup>, Sundeep Mishra<sup>3</sup>, Chaitanya Chittimuri<sup>2</sup>, Poonam Malhotra Kapoor<sup>2</sup>, Sikha Goja<sup>2</sup>, Niraj Nirmal Pandey<sup>2</sup>

<sup>1</sup>Department of Cardiothoracic and Vascular Surgery, National Institute of Medical Sciences and Research, Jaipur, Rajasthan, <sup>2</sup>Cardiothoracic Sciences Centre, All India Institute of Medical Sciences, New Delhi, <sup>3</sup>Department of Cardiology, National Institute of Medical Sciences and Research, Jaipur, Rajasthan, India.

**\*Corresponding author:**

Ujjwal K. Chowdhury,  
Director Professor, Department  
of Cardiothoracic and Vascular  
Surgery, National Institute of  
Medical Sciences and Research,  
Jaipur, Rajasthan, India.

[ujjwalchowdhury@gmail.com](mailto:ujjwalchowdhury@gmail.com)

Received: 03 November 2023  
Accepted: 14 November 2023  
Epub Ahead of Print: 23 February 2024  
Published: 15 April 2024

DOI  
[10.25259/JCCC\\_65\\_2023](https://dx.doi.org/10.25259/JCCC_65_2023)

Videos available online at  
[https://dx.doi.org/10.25259/  
JCCC\\_65\\_2023](https://dx.doi.org/10.25259/JCCC_65_2023)

**Quick Response Code:**



### ABSTRACT

We present here-in the technical details of harvesting the left radial artery in a 50-year-old man undergoing coronary artery bypass grafting. The radial artery has been harvested atraumatically using a Harmonic scalpel (Ethicon Endosurgery LLC, Johnson & Johnson Company, Guaynaba, Puerto Rico, USA) and two vessel loops by “No touch” technique, thereby preventing perioperative spasm. The postoperative recovery was uneventful.

**Keywords:** Atraumatic technique, Harvesting, Radial artery, Harmonic scalpel

### INTRODUCTION

Excellent, very late-term results of the internal thoracic artery as a graft for coronary artery bypass grafting have encouraged a search for other reliable arterial conduits for total arterial revascularization. Search conduits include the radial artery, gastroepiploic artery, inferior epigastric artery, splenic artery, and subscapular artery.<sup>[1-6]</sup>

Despite resurgence in the popularity of the radial artery as a conduit for coronary artery bypass grafting, only limited investigations are available on the histopathology and morphometry of the radial artery conduit.<sup>[7]</sup> The study has shown that the radial artery is a muscular vessel with a thin intima where the intimal endothelial cells seem flattened and are aligned along the long axis of the artery. The intima is very thin and directly rests on the internal elastic lamina.<sup>[8]</sup>

The radial artery exhibits many anatomic, surgical, and histologic advantages over other alternative arterial conduits, which has important implications on the long-term graft patency.<sup>[1-17]</sup> Microscopically, the radial artery exhibits a considerably thicker media containing a high density of smooth muscle cells as compared with the internal thoracic and gastroepiploic arteries.<sup>[4-7]</sup>

Failure of the radial artery graft is either caused by spasm or intimal hyperplasia.<sup>[11-11]</sup> The presence of thicker media makes the anastomosis technically easier but also predisposes the artery to spasm and to a greater degree of ischemia, especially in the outer layers of media.<sup>[11-5]</sup>

Electrocautery injury is also an important factor for suboptimal results with arterial conduits.<sup>[1-5]</sup> Harmonic scalpel is emerging as a useful alternative to electrocautery with the advantage of fast, safe, spasm-free harvesting, and minimal use of hemoclips for arterial branches.<sup>[5]</sup>

This is an open-access article distributed under the terms of the Creative Commons Attribution-Non Commercial-Share Alike 4.0 License, which allows others to remix, transform, and build upon the work non-commercially, as long as the author is credited and the new creations are licensed under the identical terms.

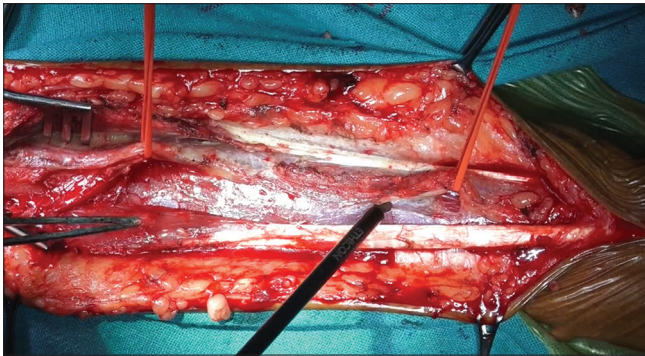
©2024 Published by Scientific Scholar on behalf of Journal of Cardiac Critical Care TSS

We describe here-in the step by step technical details of harvesting of the left radial artery using Harmonic scalpel in a 50-years-old individual undergoing triple vessel coronary artery bypass grafting. The conduits used in this patient were left internal thoracic artery to left anterior interventricular coronary artery, radial artery to first obtuse marginal, and reversed saphenous vein graft to the distal right coronary artery.

## SURGICAL TECHNIQUE

### Position and preparation of the left upper limb

After performing Allen's test, the non-dominant left upper arm is selected as the harvest site. The non-dominant forearm is surgically prepped circumferentially and draped from mid arm to hand. The forearm is extended and supinated directly perpendicular to the patient's torso [Video 1].



Video 1: Radial artery video is accessible from the portal.

### Incision

A curvilinear incision is made extending from approximately 2 cm below the antecubital crease along the length of the forearm to the wrist crease of the patient. The incision parallels the medial edge of the brachioradialis muscle.

### Development of the dissection plane between the brachioradialis and flexor carpi radialis muscle

The skin and subcutaneous tissue are incised down to the fascia overlying the flexor carpi radialis muscle. The fascial sheath overlying the superficial muscle is divided using electrocautery between 15 and 20 mv between the brachioradialis and flexor carpi radialis muscles. Care is taken not to injure the lateral cutaneous nerve overlying the brachioradialis muscle by displacing it laterally.

A self-retaining retractor is placed between the brachioradialis and flexor carpi radialis muscle. This maneuver reveals the entire course of the radial artery from the biceps tendon to the radial styloid.

### Placement of two vessel loops around the radial artery

Two-vessel loops are placed on two extremes of the radial artery using a mosquito artery forceps without injuring any perforator artery.

### Mobilization of the radial artery

The radial artery is gently mobilized to lift it from its muscular bed using a Harmonic scalpel. As the pedicle is lifted, the side branches of the radial artery are exposed. The side branches are ligated with the Harmonic scalpel. Careful, gentle, and progressively upward traction of the pedicle is performed.

### Assessment of retrograde pulsation of the radial artery

After mobilizing the entire radial artery pedicle, the radial artery is compressed digitally to document the retrograde pulsation through ulnar collateral circulation. The finger oximetry probe is also checked for pulsatile waves, with the radial artery being digitally occluded.

### Transfixation, ligation, and transection of the proximal and distal ends of the radial artery

After systemic heparinization, the proximal end of the radial artery is doubly ligated with a 2-0 silk suture and transfixed using a 3-0 polypropylene suture (Johnson and Johnson Ltd., Ethicon, LLC, San Lorenzo, USA).

Next, the distal end of the pedicle is doubly ligated using a 2-0 silk suture along the length where the radial styloid meets the radial pedicle and transfixed using a 3-0 polypropylene suture in addition.

### Use of marking pencils to avoid twisting

A marking pen is being used over the radial artery pedicle to avoid later twisting.

### Flushing of the radial artery with heparinized saline and papaverine

A small olive-tip internal mammary artery cannula is used for cannulating the proximal end of the graft and gently flushed the entire graft using heparinized saline followed by papaverine, being careful not to over-distend the vessel.

Two bulldog clamps are being placed on both ends of the radial artery and papaverine solution is retained within the graft.

The entire radial artery pedicle graft is inspected to ensure that all side branches are ligated securely.

The harvested graft is kept in a small bowl containing papaverine solution (1 mg papaverine in 1 mL saline).

### Short-and long-term results

The postoperative recovery was uneventful with stable hemodynamics and was extubated on the first operative day. There was no evidence of perioperative myocardial infarction. At 60 months of follow-up he was asymptomatic in New York Heart Association class I with left ventricular ejection fraction

of 80%. Follow-up computed tomographic angiography at 60 months revealed patent, functioning grafts with good distal run-off. There was no evidence of segmental narrowing of any grafts.

## CONCLUSION

The potential benefits of using Harmonic scalpel as an alternative to electrocautery are speedy, spasm-free harvesting with minimal manipulation and minimal use of hemoclips for arterial branches. This technique is safe, expedient and obviates any cautery-induced injury to the vessel wall, venae-comitans, and lymphatics, thus preventing perioperative spasm and myocardial ischemia. The maintenance of viable, endothelialized arterial integrity has important implications on long term graft patency. We conclude that Harmonic scalpel is a useful armamentarium for harvesting the radial artery for the purpose of an arterial conduit.

## Ethical approval

The Institutional Review Board approval is not required.

## Declaration of patient consent

The authors certify that they have obtained all appropriate patient consent.

## Financial support and sponsorship

Nil.

## Conflicts of interest

Poonam Malhotra Kapoor is the member of the editorial board of the journal.

## Use of artificial intelligence (AI)-assisted technology for manuscript preparation

The authors confirm that there was no use of artificial intelligence (AI)-assisted technology for assisting in the writing or editing of the manuscript and no images were manipulated using AI.

## REFERENCES

- Carpentier A, Guermontprez JL, Deloche A, Frechette C, DuBost C. The Aorta-to-coronary Radial Artery Bypass Graft. A Technique Avoiding Pathological Changes in Grafts. *Ann Thorac Surg* 1973;16:111-21.
- Acar C, Jebara VA, Portoghese M, Beyssen B, Pagny JY, Grare P, *et al.* Revival of the Radial Artery for Coronary Artery Bypass Grafting. *Ann Thorac Surg* 1992;54:652-60.
- da Costa FD, da Costa IA, Poffo R, Abuchaim D, Gaspar R, Garcia L, *et al.* Myocardial Revascularization with the Radial Artery: A Clinical and Angiographic Study. *Ann Thorac Surg* 1996;62:475-9.
- Curtis JJ, Stoney WS, Alford WC Jr., Burrus GR, Thomas CS Jr. Intimal Hyperplasia. A Cause of Radial Artery Aortocoronary Bypass Graft Failure. *Ann Thorac Surg* 1975;20:628-35.
- van Son JA, Smedts F, Vincent JG, van Lier HJ, Kubat K. Comparative Anatomic Studies of Various Arterial Conduits for Myocardial Revascularization. *J Thorac Cardiovasc Surg* 1990;99:703-7.
- Suma H, Wanibuchi Y, Furuta S, Isshiki T, Yamaguchi T, Takanashi R. Comparative Study between the Gastroepiploic and the Internal Thoracic Artery as a Coronary Bypass Graft. Size, Flow, Patency, Histology. *Eur J Cardiothorac Surg* 1991;5:244-7.
- Chowdhury UK, Airan B, Mishra PK, Kothari SS, Subramaniam GK, Ray R, *et al.* Histopathology and Morphometry of Radial Artery Conduits: Basic Study and Clinical Application. *Ann Thorac Surg* 2004;78:1614-21.
- Gotlieb AI, Silver MD. Atherosclerosis: Pathology and Pathogenesis. In: Schoen FJ, editor. *Cardiovascular Pathology*. 3<sup>rd</sup> ed., Ch. 4. New York: Churchill Livingstone; 2001. p. 68-106.
- Kobayashi H, Kitamura S, Kawachi K, Morita R, Konishi Y, Tsutsumi M. A Pathological and Biochemical Study of Arteriosclerosis in the Internal Thoracic Artery, a Vessel Commonly used as a Graft in Coronary Artery Bypass Surgery. *Surg Today* 1993;23:697-703.
- Stary HC, Chandler AB, Dinsmore RE, Fuster V, Glagov S, Insull W Jr., *et al.* A Definition of Advanced Types of Atherosclerosis Lesions and a Histological Classification of Atherosclerosis. A Report from the Committee on Vascular Lesions of the Council on Arteriosclerosis, American Heart Association. *Circulation* 1995;92:1355-74.
- Kaufner E, Factor SM, Frame R, Brodman RE. Pathology of the Radial and Internal Thoracic Arteries used as Coronary Artery Bypass Grafts. *Ann Thorac Surg* 1997;63:1118-22.
- Calafiore AM, Di Giammarco G, Teodori G, D'Annunzio E, Vitolla G, Fino C, *et al.* Radial Artery and Inferior Epigastric Artery in Composite Grafts: Improved Midterm Angiographic Results. *Ann Thorac Surg* 1995;60:517-23.
- Erdil N, Nisanoglu V, Eroglu T, Fansa I, Cihan HB, Battaloglu B. Early Outcomes of Radial Artery Use in all-arterial Grafting of the Coronary Arteries in Patients 65 Years and Older. *Tex Heart Inst J* 2010;37:301-6.
- Acar C, Ramsheyi A, Pagny JY, Jebara V, Barrier P, Fabiani JN, *et al.* The Radial Artery for Coronary Artery Bypass Grafting: Clinical and Angiographic Results at Five Years. *J Thorac Cardiovasc Surg* 1998;116:981-9.
- Chen AH, Nakao T, Brodman RE, Greenberg M, Charney R, Menegus M, *et al.* Early Post-operative Angiographic Assessment of Radial Grafts Used for Coronary Artery Bypass Grafting. *J Thorac Cardiovasc Surg* 1996;111:1208-12.
- Naik MJ, Abu-Omar Y, Alvi A, Wright N, Henderson A, Channon K, *et al.* Total Arterial Revascularization as a Primary Strategy for Coronary Artery Bypass Grafting. *Postgrad Med J* 2003;79:43-8.
- Bhan A, Gupta V, Choudhary SK, Sharma R, Singh B, Aggarwal R, *et al.* Radial Artery in Coronary Artery Bypass Grafting: Could the Early Results be Comparable to Internal Mammary Artery Graft? *Ann Thorac Surg* 1999;67:1631-6.

**How to cite this article:** Chowdhury UK, George N, Kanmaniyan B, Mishra S, Chittimuri C, Kapoor PM, *et al.* Step-by-Step Atraumatic Technique of Harvesting of the Radial Artery using Harmonic Scalpel: A Video Presentation. *J Card Crit Care TSS*. 2024;8:113-5. doi:10.25259/JCCC\_65\_2023