



Point of View Cardiac Critical Care

Dr. Andrew Glenn Morrow's Path of Petals and Thorns: A Critical Appraisal

Doniparthi Pradeep¹, Jaydeep Malakar¹, Chaitanya Chittimuri¹

¹Department of Cardiothoracic and Vascular Surgery, All India Institute of Medical Sciences, Delhi, India.

*Corresponding author:

Doniparthi Pradeep,
Department of Cardiothoracic
and Vascular Surgery, All India
Institute of Medical Sciences,
Delhi, India.

pradeepdhoni023.pd@gmail.com

Received: 25 February 2023
Accepted: 25 April 2023
Epub Ahead of Print: 31 July 2023
Published: 21 September 2023

DOI
10.25259/JCCC_12_2023

Quick Response Code:



ABSTRACT

In the era of 1950s and 60s, the mysterious entity of obstructive hypertrophic cardiomyopathy (HCM) ignited the minds of young physicians and surgeons to understand the pathophysiology of the disease. Although legends like Sir Russel Brock have contributed to the understanding of the pathophysiology and surgical techniques to obstructive HCM1, Dr. Andrew Glenn Morrow played a phenomenal role on his own, in understanding the pathophysiology, its effect on animal models, the provocative tests, angiographic studies, surgical techniques, and long-term results, along with his cardiology colleagues, Dr. Eugene Braunwald and Dr. Edwin C. Brockenbrough from National Heart Institute in Bethesda, Maryland. This trio has published countless research papers on Obstructive HCM.

Keywords: Andrew Glenn Morrow, Obstructive HCM, Critical appraisal

CENTRAL MESSAGE

This study was understanding the evolution of obstructive hypertrophic cardiomyopathy (HCM) and acknowledging the role of Dr. Andrew Glenn Morrow in unraveling the mysteries of obstructive HCM.

PERSPECTIVE STATEMENT

Dr. Andrew Glenn Morrow's research has greatly increased our understanding of obstructive HCM and has provided valuable insights into potential treatments for this condition. His work has been widely recognized in the medical community and has helped to improve the lives of many people with obstructive HCM.

INTRODUCTION

In the era of 1950s and 60s, the mysterious entity of obstructive HCM ignited the minds of young physicians and surgeons to understand the pathophysiology of the disease. Although legends like Brock *et al.* have contributed to the understanding of the pathophysiology and surgical techniques to obstructive HCM,^[1] Dr. Andrew Glenn Morrow played a phenomenal role on his own, in understanding the pathophysiology, its effect on animal models, the provocative tests, angiographic studies, surgical techniques, and long-term results, along with his cardiology colleagues, Dr. Eugene Braunwald and Dr. Edwin C. Brockenbrough from National Heart

This is an open-access article distributed under the terms of the Creative Commons Attribution-Non Commercial-Share Alike 4.0 License, which allows others to remix, transform, and build upon the work non-commercially, as long as the author is credited and the new creations are licensed under the identical terms.

©2023 Published by Scientific Scholar on behalf of Journal of Cardiac Critical Care TSS

Institute in Bethesda, Maryland. This trio has published countless research papers on Obstructive HCM.

HISTORICAL PERSPECTIVE

The authors want to comment on six papers, mainly contributed by Dr. A. G. Morrow [Figure 1], which delves into the understanding of the disease and the various methods to address it head on.

1. Left heart catheterization by the transbronchial route: Technic and applications in physiologic and diagnostic investigations.^[2]

This paper was published in 1957, in the acclaimed journal "Circulation." It was at that time when Zimmerman *et al.* was experimenting with retrograde left heart catheterization.^[3] To understand the hemodynamics in detail, Dr. A. G. Morrow had to spearhead the technique of the transbronchial left heart catheterization which entailed taking the pressures by inserting the needle in the posterior aspect of the left atrium through a bronchoscope guided into the left bronchus. Although it was designed by Dr. Allison and Dr. Linden, Dr. A. G. Morrow established and reproduced this technique in 500 cases with zero mortality except blood-streaked sputum for few hours following the procedure. Although percutaneous left ventricular angiogram was one of the modalities to understand the hemodynamics of the heart, its technical difficulty, chances of hemopericardium, and death had put a stalemate on this unique procedure. Dr. A. G. Morrow prioritized the safety of the patient above all else [Figure 2].^[1]

2. Functional aortic stenosis, a malformation characterized by resistance to left ventricular outflow without anatomic obstruction.^[4]

In this article, the reader can appreciate the effort put forth by Dr. A. G. Morrow in understanding the nature of the disease of obstructive HCM. This article was published in 1959 which was an era when echocardiogram was instrumental in the field of cardiology.^[10] In this article, it is evident that, Dr. A. G. Morrow attempted his best to explain all the clinical, investigative, and intraoperative findings to the unknown entity so far.

In the article, Dr. A. G. Morrow explained three case scenarios. In the first scenario, a case of subaortic stenosis (based on two zones of pressures left ventricle [LV]) was referred to him. On examining, there was no thrill radiating to the carotids. Rather he appreciated a holodiastolic murmur at the left parasternum in the heart with grossly normal mitral valve with increased left atrial pressure (16 mm Hg) with normal contour. Angiogram revealed cardiomegaly and prominent LV. In a selective left ventricular angiogram, LV cavity was small in size when compared with a normal sized aorta. On cardiotomy, he appreciated mitral regurgitation

with a grossly normal mitral valve leaflets, probably due to systolic anterior motion of mitral leaflets which were not completely understood at that stage. When he opened the aorta, he found normal aortic valve leaflets, with "no obstruction at the subaortic region." In one of the meetings, Dr. Eugene Braunwald himself recalled that he was sent for by Dr. A. G. Morrow, intraoperatively, to ascertain that there was no evidence of obstruction.^[11] He also took note of the normal endocardial lining and thickened wall.

In the second scenario, Dr. A. G. Morrow had observed the same findings with no subaortic stenosis intraoperatively. When the angiogram was repeated after 3 months, varied obstruction in each cardiac cycle was observed, although the designation of "dynamic obstruction" was yet not assigned.

In the third scenario, features of the subaortic stenosis (with a gradient of 122 mmHg) were evident, and obstruction was relieved. The patient persisted to a certain extent (Gradient 70 mmHg) 3 weeks after surgery and after 18 months following surgery, the patient had no symptoms and no gradient.

Based on three case scenarios, Dr. A. G. Morrow stated that the obstruction was evident in a contractile heart and disappeared during diastolic paralysis. He coined the term "Functional Obstruction" He also tried to explain its pathophysiology to his best. None of the three patients were hypertensive to explain ventricular hypertrophy and a normal contour of left atrial pressure was unlikely to produce ventricular changes to that extent; hence, he coined the term "Idiopathic Left Ventricular Hypertrophy." He emphasized the importance of a pathological study to find out the cause. Along with his cardiologist colleague Dr. Eugene Braunwald, he published extensive clinical, hemodynamic, and angiographic literatures.

3. Surgical treatment of idiopathic hypertrophic subaortic stenosis: technic and hemodynamic results of subaortic ventriculotomy.^[5]

This paper was published in the journal "Annals of Surgery" in 1961 describing the development of the surgical technique and hemodynamic results for obstructive HCM in three patients. In the first case, Dr. A. G. Morrow demonstrated the surgical relief of obstruction with angiographic studies; fall in gradient from 185 mmHg (Pre-operative) to 65 mmHg (5 weeks following surgery) and to 20–30 mmHg, 8 months after surgery, subsequently with phenomenal improvement in symptoms. In the second scenario, although preoperatively gradient was demonstrated, this patient was not intervened surgically even after cardiotomy thinking that obstruction was due to muscular hypertrophy. When the patient was referred to for a second redo surgery, Dr. A. G. Morrow surgically relieved the obstruction and proved the reprieve with angiographic studies. He had demonstrated the surgical technique step by step (incision, aortotomy, cardiopulmonary

bypass technique, and myocardial protection and tricks for surgical ease) with beautifully illustrated diagrams, pre- and post-operative studies including angiographic runs, pressures tracking, and roentgenograms. In the third scenario, although patient data were not reported, Dr. A. G. Morrow had maintained the myocardial contraction by maintaining the coronary perfusion to demonstrate the dynamic nature of the obstruction. Dr. A. G. Morrow had quoted transparently that Bentall *et al.*^[12] had performed this similar technique and he utilized the same concept, with extraordinary improvement in the symptoms but no post-operative hemodynamic study. In this paper, he also emphasized the importance of left heart catheterization to distinguish the lesion's discrete subaortic stenosis. He also mentioned the accentuation of pressure



Figure 1: Dr. Andrew Glenn Morrow (Courtesy: National Heart Institute, Bethesda, Maryland).

gradients with premature contraction of the ventricle due to increased left ventricular end diastolic volume, now being called the "Braunwald Brockenbrough Phenomena."

4. Operative treatment in hypertrophic subaortic stenosis. Techniques, and the results of pre- and post-operative assessments in 83 patients.^[6]

This paper was published in 1975 in the journal "Circulation." This paper describes the results and post-operative assessment after 14 years follow-up in 83 patients. It describes briefly the medical management of obstructive HCM (role of beta blockers, restriction of physical activity, weight reduction, arrhythmia management with quinidine, and role of anticoagulation with patients with atrial fibrillation), the indications of surgery, and role of provocative maneuvers (Valsalva maneuver, administration of isoproterenol, and amyl nitrite) in asymptomatic patients with significant left ventricular outflow tract (LVOT) obstruction, pre-operative optimization of the patient, anesthesia management in brief (Halothane to induce negative inotropism), and the technique of myectomy, step by step, in an incredibly meticulous manner with beautifully illustrated pictures. He followed the patients for 14 years, and published the results with transparency. If we have a glance at the results:

- Only 13 deaths among 83 post-operative patients (Necropsy was done in 12 patients to find out cause of death) and the cause of death were explained meticulously in detail
- Conduction heart block was only observed in three patients, all of whom required pacemaker insertion
- Ventricular septal defect (VSD) was recorded in five patients (two early, three late). Only one among the five patients required surgical closure of VSD

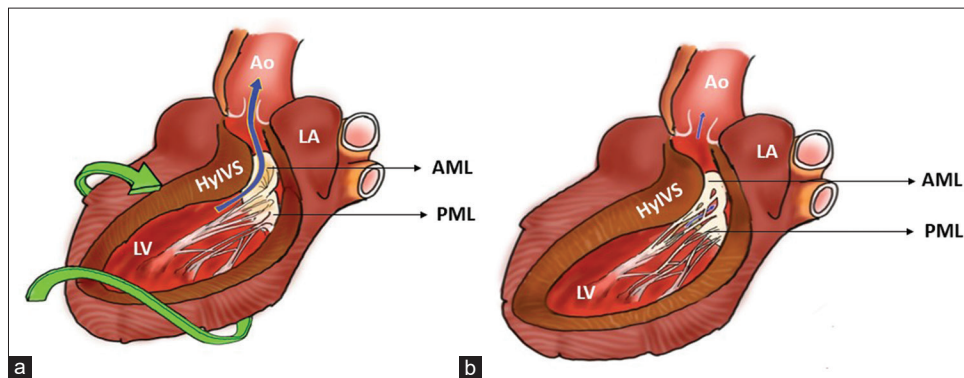


Figure 2: (a) The phase of early systole. In early systole, spiral contraction of the LV leads to ejection of blood from the LV to the Aorta. (b) The phase of mid systole. In mid systole, a part of the anterior leaflet of the mitral valve moves anteriorly and toward the base, eventually coming into contact with the septum. This is known as systolic anterior motion and it leads to failure of leaflet coaptation and subsequent mitral regurgitation directed posteriorly into the left atrium. Ao: Aorta, LA: Left atrium, LV: Left ventricle, AML: Anterior mitral leaflet, PML: Posterior mitral leaflet, HyIVS: Hypertrophied interventricular septum (Basal part), Green spiral arrow: Helix configuration of myocardial fibers, Blue arrow: Direction of blood flow.

- New York Heart Association (NYHA) status in 59 survivors: After 6 years of follow-up, none of the patients were in NYHA IV, and only one patient was in NYHA III, and rest of the patient are in NYHA I and NYHA II (29)
 - Hemodynamics studies: Dr. A. G. Morrow had documented all pre-operative and post-operative LVOT gradients (rest and provocative) with illustrated graphs proving the surgical relief of left ventricular outflow tract obstruction (LVOTO)
 - Electrocardiographic changes demonstrating pre- and post-operative conduction system blocks and arrhythmias
 - Echocardiography: As the modality of echocardiography was in its initial stages in utilization, it was performed in 16 patients only. It was instrumental in understanding the mitral leaflet motion. In contemporary times, the concept of systolic anterior motion of mitral valve was demonstrated by Henry *et al.*^[13] Another finding in echocardiography showed a decrease in ventricular free wall thickness. It was postulated that free wall thickness is secondary to LVOTO
 - Dr. A. G. Morrow believed that mitral regurgitation would eventually settle after correction of obstructive HCM and it was unnecessary to subject the patient to a prosthetic material. This was in contrast to Cooley *et al.* who believed that a mitral valve replacement, along with myectomy, yielded better results.^[14]
5. Can outflow obstruction be induced within the normal LV?^[7]

This article was published in the American Journal of Cardiology in 1965. In this paper, Dr. A. G. Morrow explained the animal experiments in controlled conditions to understand the LVOT obstruction in normal animals. It shone a light to the understanding of the pathophysiology of LVOT gradients varying under volume change and vasopressor changes.

6. The experimental production of hypertrophic subaortic stenosis.^[8]

Although this paper was co-authored by Dr. A. G. Morrow, the discussion of his role in the creation of an animal model is worth deliberating. They had done a wedge resection of the aorta, thereby inducing a coarctation which gave additional afterload in developing left ventricular hypertrophy. Once the LV hypertrophy was developed, they resected the coarcted segment and performed end to end anastomosis there by creating an animal model. Although it was not similar to obstructive HCM, it was useful in understanding its reaction to provocative maneuvers with digitalis, isoproterenol, and amyl nitrate and also in understanding the Braunwald Brockenbrough Phenomena by inducing premature ventricular contraction.

The authors have discussed only six important articles of Dr. A. G. Morrow; however, he was a part of all

pharmacological tests, provocative maneuvers, and other experiments of Braunwald *et al.* and Brockenbrough in a direct or an indirect manner.^[5,15-17] He has wrapped almost all knowledge starting from clinical features to follow-up, leaving nothing to excavate further into the domain of obstructive HCM. At times, it is the irony that he passed away with obstructive HCM which is a known fact to the entire fraternity of cardiac surgery.

CONCLUSION

Although, Dr. A. G. Morrow contributed immense knowledge to the domain of obstructive HCM, the authors want to add a little to it. Spiral contractile nature of the heart is explained by the Torrent Guasp model which was elaborated by the Spanish Cardiologist Torrent-Guasp *et al.*,^[9] in which he dissected hundreds of animals' hearts. He observed that the heart ventricles represent a continuous muscular band folded on itself as a helix during embryonic development. Close to birth, the myocardial band creates a septum that separates the two ventricular chambers. The elliptical shape formed by the overlapping ascending and descending segments of the apical loops accounts for the natural helix formation. The authors believe that a spiral contractile nature of the heart may explain the dynamic LVOTO in obstructive HCM.

Acknowledgment

The authors want to thank the National Heart Institute for providing the picture of Dr. Andrew Glenn Morrow.

Declaration of patient consent

Patient's consent not required as patients identity is not disclosed or compromised.

Financial support and sponsorship

Nil.

Conflicts of interest

There are no conflicts of interest.

REFERENCES

1. Brock R, Milstein BB, Ross DN. Percutaneous left ventricular puncture in the assessment of aortic stenosis. *Thorax* 1956;11:163-71.
2. Morrow AG, Braunwald E, Haller JA Jr., Sharp EH. Left heart catheterization by the transbronchial route: Technic and applications in physiologic and diagnostic investigations. *Circulation* 1957;16:1033-9.
3. Zimmerman HA, Scott RW, Becker NO. Catheterization of the left side of the heart in man. *Circulation* 1950;1:357-9.

4. Morrow AG, Braunwald E. Functional aortic stenosis; A malformation characterized by resistance to left ventricular outflow without anatomic obstruction. *Circulation* 1959;20:181-9.
5. Morrow AG, Brockenbrough EC. Surgical treatment of idiopathic hypertrophic subaortic stenosis: Technic and hemodynamic results of subaortic ventriculo myotomy. *Ann Surg* 1961;154:181-9.
6. Morrow AG, Reitz BA, Epstein SE, Henry WL, Conkle DM, Itscoitz SB, *et al.* Operative treatment in hypertrophic subaortic stenosis. Techniques, and the results of pre and postoperative assessments in 83 patients. *Circulation* 1975;52:88-102.
7. Morrow AG, Vasko JS, Henney RP, Brawley RK. Can outflow obstruction be induced within the normal left ventricle? *Am J Cardiol* 1965;16:540-6.
8. McLaughlin JS, Morrow AG, Buckley MJ. The experimental production of hypertrophic subaortic stenosis. *J Thorac Cardiovasc Surg* 1964;48:695-703.
9. Torrent-Guasp F, Buckberg GD, Clemente C, Cox JL, Coghlan HC, Gharib M. The structure and function of the helical heart and its buttress wrapping. I. The normal macroscopic structure of the heart. *Semin Thorac Cardiovasc Surg* 2001;13:301-19.
10. Edler I, Hertz CH. The use of ultrasonic reflectoscope for the continuous recording of the movement of heart walls. *Clin Physiol Funct Imaging* 1954;24:40-58.
11. Braunwald E. Hypertrophic cardiomyopathy: The first century 1869-1969. *Glob Cardiol Sci Pract* 2012;2012:5.
12. Bentall HH, Cleland WP, Oakley CM, Shah PM, Steiner RE, Goodwin JF. Surgical treatment and post-operative haemodynamic studies in hypertrophic obstructive cardiomyopathy. *Br Heart J* 1965;27:585-94.
13. Henry WL, Clark CE, Griffith JM, Epstein SE. Mechanism of left ventricular outflow obstruction in patients with obstructive asymmetric septal hypertrophy (idiopathic hypertrophic subaortic stenosis). *Am J Cardiol* 1975;35:337-45.
14. Cooley DA, Leachman RD, Hallman GL, Gerami S, Hall RJ. Idiopathic hypertrophic subaortic stenosis. Surgical treatment including mitral valve replacement. *Arch Surg* 1971;103:606-9.
15. Braunwald E, Oldham HN Jr., Ross J Jr., Linhart JW, Mason DT, Fort L 3rd. The circulatory response of patients with idiopathic hypertrophic subaortic stenosis to nitroglycerin and to the valsalva maneuver. *Circulation* 1964;29:422-31.
16. Braunwald E, Morrow AG. Obstruction to left ventricular outflow. Current criteria for the selection of patients for operation. *Am J Cardiol* 1963;12:53-9.
17. Morrow AG. Hypertrophic subaortic stenosis. Some physiologic concepts and the role of operative treatment. *Arch Surg* 1969;99:677-83.

How to cite this article: Pradeep D, Malakar J, Chittimuri C. Dr. Andrew Glenn Morrow's path of petals and thorns: A critical appraisal. *J Card Crit Care TSS* 2023;7:169-73.