



Case Series Cardiac Critical Care

On-table Extubation Facilitated by Regional Analgesic Techniques Combined with General Anesthesia for PDA Ligation: A Case-series and Literature Review

Rohan Magoon¹, Jes Jose², Brajesh Kaushal³, R. P. Kaushal³, Praveen Sharma⁴

¹Department of Anaesthesia, Atal Bihari Vajpayee Institute of Medical Sciences and Dr. Ram Manohar Lohia Hospital, New Delhi, ²Department of Cardiac Anesthesiology, Sri Jayadeva Institute of Cardiovascular Sciences and Research, Bengaluru, Karnataka, Departments of ³Anesthesiology and ⁴Cardiothoracic and Vascular Surgery, Gandhi Medical College, Bhopal, Madhya Pradesh, India.

*Corresponding author:

Brajesh Kaushal,
Department of Anaesthesiology,
Gandhi Medical College,
Bhopal, Madhya Pradesh, India.

brajeshkaushal3@gmail.com

Received: 19 April 2023
Accepted: 14 May 2023
EPub Ahead of Print: 14 June 2023
Published: 21 September 2023

DOI
10.25259/JCCC_22_2023

Quick Response Code:



ABSTRACT

Background: An increasing embracement of safer regional techniques as pivotal components of multimodal analgesia regimen has made fast-tracking possible following pediatric cardiac surgery. Speaking of fast-tracking in pediatrics, the feasibility of on-table extubation (OTE), and its' potential benefits are also being ardently researched with simultaneous emphasis on appropriate patient selection and adequate perioperative safety.

Case Series: We report eight consecutive pediatric cases featuring a combination of serratus anterior plane block (SAPB) or erector spinae plane block (ESPB) to general anesthesia (GA) for patent ductus arteriosus (PDA) ligation through a left thoracotomy incision. Following induction of GA, the left-sided SAPB was performed in five patients and the other three patients received left-sided ESPB, each with 0.5 mL/kg of 0.2% ropivacaine. Demonstrating a mean intraoperative fentanyl requirement of 3.25 ± 0.71 $\mu\text{g}/\text{kg}$, OTE could be successfully contemplated in all the 8 patients. Subsequently, the post-operative face, leg, activity, cry, and consolability (FLACC) score was recorded at 1, 2, 4, 6, 8, and 12 h. Meanwhile, all the patients depicted acceptable pain scores till 4 h, administration of 0.5 $\mu\text{g}/\text{Kg}$ rescue fentanyl was necessitated in three patients each at 6-h and 8-h postoperatively (given FLACC scores ≥ 4), amounting to a mean 0.375 ± 0.23 $\mu\text{g}/\text{kg}$ post-operative fentanyl requirement. All patients received intravenous paracetamol at 8-h postoperatively. No block-related complication or need for reintubation was discovered.

Conclusion: Incorporation of fascial plane blocks (SAPB or ESPB) to the conduct of GA for PDA ligation, allowed for safe OTE in our experience, due to an opioid-sparing potential.

Keywords: Erector spinae plane block, On-table extubation, Serratus anterior plane block, Patent ductus arteriosus, Pediatric cardiac surgery

INTRODUCTION

Multimodal analgesia is at the cornerstone of paving the way for enhanced recovery after cardiac surgery (ERACS).^[1] Given fast-tracking is an important component of ERACS, it needs to be understood that the former can efficiently materialize only in the background of safe opioid-sparing analgesic regimens.^[2] In this context, the literature highlights the growing role of novel fascial plane blocks in formulating a regional-centric perioperative analgesic scheme.^[3-5]

This is an open-access article distributed under the terms of the Creative Commons Attribution-Non Commercial-Share Alike 4.0 License, which allows others to remix, transform, and build upon the work non-commercially, as long as the author is credited and the new creations are licensed under the identical terms.

©2023 Published by Scientific Scholar on behalf of Journal of Cardiac Critical Care TSS

At the same time, the subject of on-table extubation (OTE) following cardiac surgery is being ardently researched with respect to its feasibility and potential benefits.^[6-8] Meanwhile the advantage of resource utilization containment is intuitive, the concurrent need for an appropriate patient selection to ensure adequate perioperative safety can also not be undermined.^[9] Focusing on the predictors of success/failure of OTE in cardiac surgery, recent literature suffices to suggest a prudent approach to decision-making on the contextual possibility of OTE.^[6-9] Withstanding, we attempted OTE following a closed-heart procedure of patent ductus arteriosus (PDA) ligation under general anesthesia (GA) wherein opioid-sparing was assisted by the inclusion of fascial plane blocks (erector spinae plane block [ESPB] and serratus anterior plane block [SAPB]), and report our experience as a case series.

CASE SERIES

After discussing the anesthesia-analgesia plan with the parents, written informed consent was obtained to include eight consecutive patients posted for PDA ligation. A standard posterolateral thoracotomy incision at the level of the left fifth intercostal space was employed in all the patients. In instances of combined procedure, non-thoracotomy surgical approach, preexisting renal or hepatic impairment, local anesthetic allergy, coagulopathy, and/or parental refusal for consent, the patients were excluded.

The patients were premedicated with oral midazolam 0.5 mg/kg suspension half an hour before surgery. Routine intraoperative monitoring with 5-lead electrocardiogram, non-invasive blood pressure, and pulse oximetry was instituted, and, a functioning peripheral intravenous (IV) line was secured. All the patients received 2µg/kg IV fentanyl prior to anesthetic induction with ketamine 2 mg/kg and, muscle relaxation with cisatracurium 0.15 mg/kg to facilitate smooth endotracheal intubation. While volume-control ventilation with 6–8 mL/kg of tidal volume was used to maintain an end-tidal carbon dioxide of around 35 mmHg, an invasive blood pressure monitoring access was simultaneously established. Anesthesia was maintained with supplemental cisatracurium doses and an admixture of oxygen-air-sevoflurane to achieve the minimum alveolar concentration of 1.0 alongside 0.5 fractions of inspired oxygen concentration.

The procedure of ultrasound-guided fascial plane blocks performed under aseptic precautions with an 8–13MHz probe (Epiq 7 USA) and a 22-gauge 50 mm Stimuplex A needle (B. Braun, Melsungen Germany) is described as follows:

Ultrasound-guided SAPB was performed with the patients in the right lateral decubitus position. A linear ultrasound probe

was placed over the mid-clavicular region of the thorax. The ribs were counted down until the fifth rib was identified in the mid-axillary line. Latissimus dorsi, teres major, and serratus muscle were identified from the skin toward the ribs. The needle was inserted in the plane with ultrasound guidance and reached deep into the serratus anterior muscle. Under real-time guidance, 0.2% ropivacaine 0.5 mL/kg was injected below the serratus anterior muscle plane after careful negative aspiration [Figure 1: a1 and a2].

Ultrasound-guided ESPB was contemplated with the patient in a right lateral decubitus position under all aseptic precautions. A high-frequency lineal ultrasound probe was placed in a longitudinal position over the T₄ transverse process lateral to the spinous process. All the structures including the trapezius, rhomboid major, and erector spinae muscle were identified above the underlying transverse process, a 5 cm 22-gauge stimuplex A block needle was inserted in-plane in a cephalo-caudad direction. When the needlepoint reached below the erector spinae muscle at the corresponding transverse process, 0.2% ropivacaine 0.5 mL/kg was injected under ultrasound guidance after careful negative aspiration [Figure 1: b1 and b2].

Across the perioperative period, the hemodynamics were continuously monitored and recorded for all patients at these specific time points: Baseline, skin incision, rib retraction, intercostal drain (ICD) insertion, and skin closure. The time points of skin incision, rib retraction, and ICD insertion corresponded to the expected periods of surgical stimulation. Herein, a concomitant increase in the systemic blood pressure and heart rate of greater than 10% over the baseline was managed with an intraoperative administration of 1µg/Kg fentanyl. Nonetheless, nitroglycerine 0.5 µg/kg/min infusion was started 5 min prior to PDA clamping, to assist the surgical conduct and then tapered off in all the patients.

On the completion of the procedure, the patients were considered for extubation on ensuring hemodynamic stability, normothermia, and no signs of upper airway edema, electrolyte abnormality, or early surgical complications, such as bleeding. Subsequently, residual neuromuscular blockade was reversed with neostigmine 50 µg/kg and glycopyrrolate 10 µg/kg. The patient's airway was extubated once neuromuscular blockade was adequately reversed and spontaneous breathing was accompanied with acceptable respiratory and arterial blood gas parameters. Post-extubation, oxygen was administered via nasal cannula, and the patients were shifted to the cardiac intensive care unit (ICU).

In the ICU, the post-operative pain scores of the patients were assessed using face, leg, activity, cry, and consolability score (FLACC scored from 0 to 10) at 1 h, 2 h, 4 h, 6 h, 8 h, and 12 h. Documentation of FLACC score ≥4 for a given patient at any of the above time points was treated with a

post-operative rescue analgesic dose of 0.5 µg/kg fentanyl IV. All the patients received IV paracetamol, 15 mg/kg 8 hourly.

[Table 1] outlines the characteristics of the patients included in the case series. Out of the eight patients, three received ESPB with the other five receiving SAPB. With the surgical duration ranging from 77 to 100 min, the corresponding need for time-point based 1 µg/kg fentanyl supplementation was as follows: Two at skin incision, six at rib retraction, and two at ICD insertion. Therefore, the mean intraoperative fentanyl cumulative dose amounted to 3.25 ± 0.71 µg/kg, given all patients were administered 2 µg/kg fentanyl at anesthetic induction [Table 2]. While all the patients depicted acceptable post-operative pain scores till 4 h, 3 patients each at 6-h and 8-h postoperatively

demonstrated FLACC scores ≥ 4 . The former necessitated administration of 0.5 µg/kg rescue fentanyl to these patients accounting for a mean postoperative fentanyl requirement of 0.375 ± 0.23 µg/kg [Table 2]. The associated mean post-operative FLACC scores of the eight patients at 1 h, 2 h, 4 h, 6 h, 8 h, and 12 h are also outlined in [Table 2]. No patient developed the need for reintubation or any block-related complications.

DISCUSSION

The index case series highlighting the feasibility of OTE in a pediatric cardiac surgical cohort undergoing PDA ligation is pertinent to the modern-day context of ERACS.^[1,2] Notably, the inclusion of ESPB or SAPB in the anesthesia regime and

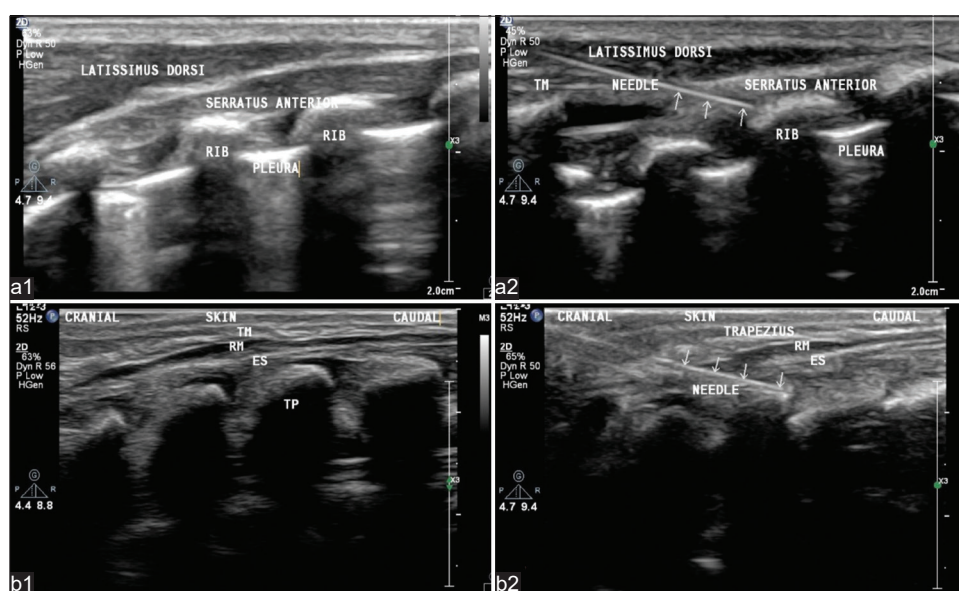


Figure 1: Depiction of the serratus anterior plane block sonoanatomy (a1); Ultrasonographic image with the needle directed (at the level of the fifth rib) toward the optimal plane just below the serratus anterior muscle (a2); Sonoanatomy of erector spinae plane block (b1); The in-plane needle tract and tip can be visualized below the erector spinae muscle (b2).

Table 1: Baseline and operative characteristics of the patients.

S. No.	Age/Sex	Weight (kg)	Regional anesthesia	Surgical duration (Minutes)	Intraoperative hemodynamics SBP/DBP (HR)				
					Baseline	Skin incision	Rib retraction	ICD insertion	Skin closure
1.	3 m*/F	4.5	SAPB	80	82/42 (120)	84/44 (124)	85/43 (121)	87/50 (113)	88/52 (115)
2.	6m/F	5.5	ESPB	95	84/44 (118)	100/46 (131) [§]	102/48 (133) [§]	89/51 (113)	90/52 (110)
3.	9 m/F	6	SAPB	100	94/48 (111)	117/48 (130) [§]	115/51 (131) [§]	97/53 (101)	98/57 (102)
4.	10 m/F	6.5	SAPB	82	90/48 (109)	93/50 (111)	110/53 (133) [§]	96/55 (102)	95/58 (104)
5.	11 m/M	7.5	ESPB	85	96/48 (112)	97/49 (110)	94/51 (113)	113/57 (132) [§]	98/59 (104)
6.	1y 2 m/M	8	SAPB	90	92/46 (109)	95/48 (113)	114/50 (127) [§]	116/56 (130) [§]	98/60 (105)
7.	1y 3 m/F	8	SAPB	80	102/48 (112)	107/50 (114)	124/50 (130) [§]	109/58 (107)	111/60 (109)
8.	1y 6 m/M	10	ESPB	77	98/48 (107)	102/50 (109)	118/51 (128) [§]	104/54 (104)	105/56 (106)

DBP: Diastolic blood pressure, ESPB: Erector spinae plane block, HR: Heart rate, ICD: Intercostal drain, SAPB: Serratus anterior plane block, SBP: Systolic blood pressure. *Corrected age in view of 1-month preterm birth, [§]Simultaneous rise of $\geq 10\%$ in SBP/DBP and HR

Table 2: Perioperative analgesic requirements and postoperative pain score.

Perioperative Analgesia Requirements*		
Intraoperative fentanyl requirement		3.250±0.71 µg/kg
Rescue post-operative fentanyl requirement		0.375±0.23 µg/kg
Post-operative FLACC score*	No. of patients requiring rescue in view of FLACC ≥4	
1 h	1.375±0.52	0
2 h	1.625±0.52	0
4 h	2.250±0.71	0
6 h	3.125±1.13	3
8 h	3.375±1.51	3
12 h	3.000±0.00	0

*Values expressed as mean±SD. (FLACC: Face, Leg, Activity, Cry, Consolability, scored from 0 to 10)

the consequential opioid-sparing facilitated safe OTE in our patients.

First, the literature surrounding OTE in cardiac surgery is intriguing, to say the least.^[6-9] Talking beyond a lower resource utilization with OTE, there remain concerns about safe adoption across high-risk cardiac surgical patients. This is hinted by the findings of the recent Hawkins *et al.* study delineating a significantly higher rate of reintubation in the background of OTE when compared to the patients extubated within 6 h of ICU admission (4.3% vs. 1.8%, $P = 0.008$).^[9] While the aforesaid findings are concerning enough to emanate from a large decade-long society of thoracic surgeons database, Baehner *et al.* study impresses on the other side of the story.^[6,9] The latter attributes merit to OTE in pediatric cardiac surgery due to the elucidation of improved postoperative outcomes in their patients.^[6] This emphasizes an inherent need for prudent patient selection. Appropriate to the context, Fukunishi *et al.* propose accentuated chances of OTE feasibility in the lower Risk Adjustment in Congenital Heart Surgery method categories.^[8] Withstanding, we chose a homogenous surgical subset undergoing a closed-heart procedure of PDA ligation.

Second, the feasibility of OTE must be addressed in close conjunction with the general perioperative anesthesia management and opioid-sparing, in particular.^[1,2,10-12] Mittnacht *et al.* propound curtailing the cumulative fentanyl dose to 3–5 µg/kg while contemplating OTE following cardiac surgery.^[7] The overall fentanyl requirements (3.25 ± 0.71 µg/kg intraoperative and 0.375 ± 0.23 µg/kg post-operative) were well within the pre-specified limits in our patients.

Third, the role of novel and safe fascial plane blocks in limiting the perioperative opioid requirements in cardiac surgery is captivating attention.^[3-5,13] In our own previously

published experiences with SAPB in thoracotomies and ESPB in sternotomies for pediatric cardiac surgery, we could achieve opioid-sparing and fast-tracking with the same.^[3,4] This motivated us to contemplate OTE with the use of ESPB and SAPB, as a follow-up of our previous work. Interestingly, a systematic review of the role of ESPB in diverse pediatric surgeries by Holland and Bosenberg revealed 70.1% of the included patients manifested ≤10% hemodynamic response to skin incision (surrogate definition of a successful block, as proposed by the authors).^[14] Much in accordance, 75% (6/8 of our patients) demonstrated <10% hemodynamic response to skin incision. With regards to the period of adequate analgesia, the pattern of post-operative rescue requirements in our patients implies an analgesic duration congruent to the relevant literature on fascial plane blocks.^[15,16]

Talking of the literature specific to PDA ligation, Nishinaka *et al.* reported a single case of OTE assisted by thoracic epidural anesthesia combined with GA for PDA ligation.^[17] However, with the advent of safer fascial plane blocks, the motivation toward employing regional techniques with GA is escalating in the cardiac surgical arena.^[18,19] Carvalho *et al.* published case reports of pre-term twins wherein they combined ESPB with GA for PDA ligation.^[5] They could attain opioid-sparing with ESPB and could extubate the premature neonates at 24 h and 34 h, respectively. Understandably, PDA has links with prematurity which further adds the incremental need for achieving opioid-sparing.^[5] Nonetheless, the youngest infant in our case series had a corrected age of 3 months, adjusted for 1-month pre-term birth [Table 1]. Having said that, our experience adds to the existing literature^[5,17,20] elaborating on the role of fascial plane blocks in ensuring safe OTE following PDA ligation by accomplishing effective pain management alongside predictable opioid-sparing. As far as the extrapolation of the plausible benefits to a more inclusive cardiac surgical subset is concerned, prospective research is warranted drawing motivation from our case series and a very recent retrospective cohort analysis by Revollo *et al.* hinting reduced extubation times with fascial plane blocks.^[21,22] Herein, the use of analgesic adjuvants and fascial plane catheters can indeed be of additional help in achieving the aforementioned.

CONCLUSION

Incorporation of fascial plane blocks like ESPB or SAPB to the conduct of GA for PDA ligation, allowed for safe OTE in our experience, due to an opioid-sparing potential. Meanwhile, the role of fascial plane blocks in facilitating early tracheal extubation appears promising, future research is mandated with a concurrent focus on perioperative efficacy and safety across diverse cardiac surgical settings.

Author contributions

RM: Conceptualizing and lead in writing the draft; JJ: Literature review and assistance in writing the draft; BK: Conceptualizing, literature review, and data collection; RPK and PS: Supervision and reviewing the final draft.

Declaration of patient consent

The authors certify that they have obtained all appropriate patient consent.

Financial support and sponsorship

Nil.

Conflicts of interest

There are no conflicts of interest.

REFERENCES

- Magoon R, Jose J. Multimodal analgesia in paving the way for enhanced recovery after cardiac surgery. *Braz J Cardiovasc Surg* 2022;38:316-7.
- Choudhury A, Magoon R, Sahoo S, Sehgal L. Opioid free cardiac surgery: Opportunities and obstacles. *J Cardiothorac Vasc Anesth* 2020;34:567-8.
- Kaushal B, Chauhan S, Saini K, Bhoi D, Bisoi AK, Sangdup T, *et al.* Comparison of the efficacy of ultrasound-guided serratus anterior plane block, pectoral nerves ii block, and intercostal nerve block for the management of postoperative thoracotomy pain after pediatric cardiac surgery. *J Cardiothorac Vasc Anesth* 2019;33:418-25.
- Kaushal B, Chauhan S, Magoon R, Krishna NS, Saini K, Bhoi D, *et al.* Efficacy of bilateral erector spinae plane block in the management of acute postoperative surgical pain after pediatric cardiac surgeries through a midline sternotomy. *J Cardiothorac Vasc Anesth* 2020;34:981-6.
- Carvalho EV, Marques JL, Santos MJ. General anesthesia combined with erector spinae plane block for ductus arteriosus closure: Two case reports. *Braz J Anesthesiol* 2020;70:171-4.
- Baehner T, Pruemmer P, Vergnat M, Asfour B, Straßberger-Nerschbach N, Kirfel A, *et al.* Effects of on-table extubation after pediatric cardiac surgery. *J Clin Med* 2022;11:5186.
- Mittnacht AJ, Thanjan M, Srivastava S, Joashi U, Bodian C, Hossain S, *et al.* Extubation in the operating room after congenital heart surgery in children. *J Thorac Cardiovasc Surg* 2008;136:88-93.
- Fukunishi T, Oka N, Yoshii T, Kobayashi K, Inoue N, Horai T, *et al.* Early extubation in the operating room after congenital open-heart surgery. *Int Heart J* 2018;59:94-8.
- Hawkins AD, Strobel RJ, Mehaffey JH, Hawkins RB, Rotar EP, Young AM, *et al.* Operating room versus intensive care unit extubation within 6 hours after on-pump cardiac surgery: Early results and hospital costs. *Semin Thorac Cardiovasc Surg* 2022;S1043-0679(22)00272-6
- Magoon R, Choudhury A. Opioid free anesthesia: Is it too early to bid adieu? *Can J Anaesth* 2019;66:1268-9.
- Dey S, Kohli JK, Magoon R, ItiShri I, Kashav RC. Feasibility of opioid-free anesthesia for cervical rib excision: A case series and review of literature. *J Cardiac Crit Care TSS* 2021;5:208-13.
- Magoon R, Dhawan I, Makhija N. On-table extubation following off-pump bidirectional cavopulmonary anastomosis: Two sides of the coin. *Ann Card Anaesth* 2018;21:461-2.
- Cosarcan SK, Sezer ÖA, Gürkahraman S, Erçelen Ö. Regional analgesia techniques for effective recovery from coronary artery bypass surgeries: A retrospective study involving the experience of a single center. *J Cardiothorac Surg* 2022;17:170.
- Holland EL, Bosenberg AT. Early experience with erector spinae plane blocks in children. *Paediatr Anaesth* 2020;30:96-107.
- Aydin T, Balaban O, Acar A. Ultrasound guided continuous erector spinae plane block for pain management in pulmonary malignancy. *J Clin Anesth* 2018;46:63-4.
- Berthoud V, Ellouze O, Nguyen M, Konstantinou M, Aho S, Malapert G, *et al.* Serratus anterior plane block for minimal invasive heart surgery. *BMC Anesthesiol* 2018;18:144.
- Nishinaka A, Kamei M, Sakakura Y, Kimura J, Nakanishi M, Yoshizumi Y, *et al.* On-table extubation in a low-birth-weight neonate who underwent patent ductus arteriosus ligation under combined general and thoracic epidural anesthesia. *Cardiovasc Anesth* 2017;21:75-8.
- Magoon R, Makhija N, Sarkar S. Erector spinae plane block and cardiac surgery: A closer look. *J Clin Anesth* 2020;60:8.
- Magoon R, Kaushal B, Chauhan S, Bhoi D, Bisoi AK, Khan MA. A randomised controlled comparison of serratus anterior plane, pectoral nerves and intercostal nerve block for post-thoracotomy analgesia in adult cardiac surgery. *Indian J Anaesth* 2020;64:1018-24.
- Hagen J, Devlin C, Barnett N, Padover A, Kars M, Bebic Z. Erector spinae plane blocks for pediatric cardiothoracic surgeries. *J Clin Anesth* 2019;57:53-4.
- Harris KC, Holowachuk S, Pitfield S, Sanatani S, Froese N, Potts JE, *et al.* Should early extubation be the goal for children after congenital cardiac surgery? *J Thorac Cardiovasc Surg* 2014;148:2642-7.
- Revollo SO, Echevarria GC, Fullerton D, Ramirez I, Farias J, Lagos R, *et al.* Intraoperative fascial plane blocks facilitate earlier tracheal extubation and intensive care unit discharge after cardiac surgery: A retrospective cohort analysis. *J Cardiothorac Vasc Anesth* 2022;37:437-44.

How to cite this article: Magoon R, Jose J, Kaushal B, Kaushal RP, Sharma P. On-table extubation facilitated by regional analgesic techniques combined with general anesthesia for PDA ligation: A case-series and literature review. *J Card Crit Care TSS* 2023;7:153-7.