



Point of Technique Cardiac Critical Care

Technical Details of a Novel Surgical Procedure of Anomalous Left Coronary Artery from the Pulmonary Trunk in a Child Using Autogenous Aortic and Pulmonary Arterial Flaps (UKC's Modification): A Video Presentation

Ujjwal K. Chowdhury¹, Niwin George², Shikha Goja²

Department of ¹Cardiothoracic Surgery, National Institute of Medical Sciences and Research, Rajasthan; ²Cardiothoracic Sciences Centre, All India Institute of Medical Sciences, New Delhi, India.

***Corresponding author:**

Ujjwal K. Chowdhury,
Director Professor, Department
of Cardiothoracic and Vascular
Surgery, National Institute of
Medical Sciences and Research,
Jaipur, Rajasthan, India.

ujjwalchow@rediffmail.com

Received: 03 November 2023

Accepted: 28 November 2023

Published: 22 January 2024

DOI

10.25259/JCCC_24S1_UC

Video available online at

https://dx.doi.org/10.25259/JCCC_24S1_UC

ABSTRACT

A 18-months-old male child diagnosed with anomalous origin of left coronary artery from the left posterior pulmonary sinus underwent the modification of the “trapdoor” technique, wherein the anomalous left coronary artery was detached from the pulmonary arterial sinus, and combined aortic and pulmonary arterial flaps were used to augment its length. The postoperative recovery was uneventful.

Keywords: Anomalous left coronary artery, Pulmonary trunk, Autogenous aortic, Pulmonary arterial flaps

INTRODUCTION

Creation of a dual coronary arterial system is the preferred surgical option in patients in whom the anomalous artery originated from the pulmonary trunk.^[1-20] It eliminates the steal phenomena and restores physiological antegrade flow to the ischemic left ventricular myocardium. Among the variety of available surgical options, direct reimplantation of an anomalous left coronary artery into the aorta is the preferred option.^[1-4]

However, direct reimplantation of the anomalous left coronary artery may be technically more difficult and hazardous if the anomalous orifices are located in the non-facing or left posterior sinus and in late presenters with diminished vessel elasticity and extensive formation of collateral vessels around the pulmonary sinuses.^[1-10] If the distance between the aorta and the anomalous left coronary artery is longer, it would require extensive dissection for mobilization of the proximal part of the coronary artery to reach the aorta with the potential for tearing and resultant catastrophic bleeding.^[1,7-10]

In these situations, three techniques of arterial elongation are available to account for lack of arterial length. The techniques include interposition of a free segment of subclavian artery,^[11,12] creation of an aortopulmonary window with an intrapulmonary baffle,^[6] and prolongation of

This is an open-access article distributed under the terms of the Creative Commons Attribution-Non Commercial-Share Alike 4.0 License, which allows others to remix, transform, and build upon the work non-commercially, as long as the author is credited and the new creations are licensed under the identical terms.

©2024 Published by Scientific Scholar on behalf of Journal of Cardiac Critical Care TSS

flaps of pulmonary arterial wall with or without anastomosis to the right subclavian artery.^[3,9,12-17]

The reported patency rate of free subclavian artery implantation is 80% at 11 months.^[11] Although an intrapulmonary tunnel can be performed in all cases of the anomalous left coronary artery from the pulmonary trunk, the technique has been associated with baffle obstruction, pulmonary valvular dysfunction, and fistulous communication of the intrapulmonary baffle.^[2,3,9,10] In addition, the creation of an intrapulmonary tunnel may be technically difficult when the origin of the anomalous left coronary artery is located adjacent to a pulmonary valvular leaflet.

To overcome the limitations of these procedures, diverse technical modifications have been proposed to elongate the main stem of the left coronary artery, each having its advantages and disadvantages.^[3,12-17]

We developed a new trapdoor technique for reimplantation using combined autogenous aortic and pulmonary arterial flaps for augmentation of its length in situations when a direct connection was not possible. In 2008, we published the technical details and mid-term results on four selected patients aged three months, six months, 18 months, and 27 years.^[21] Subsequently, between 2008 and 2022, we used our modified trapdoor technique on 16 additional patients with anomalous left coronary arteries from the pulmonary trunk due to a lack of coronary arterial length, diminished vessel elasticity, and extensive collaterals around the pulmonary sinuses, which prevented direct translocation.

Thus, there were nine forces driving our decision-making for anatomic repair of the anomalous left coronary artery from the pulmonary trunk:

- The desire to create a dual coronary arterial system by reimplanting the anomalous left coronary artery to the aortic sinus which will offer hemodynamic advantages.
- The desire to obtain adequate operative exposure and direct access to the left coronary artery and its neo-aortic location.
- The desire to utilize our technique in all cases irrespective of the location of the anomalous orifices within the pulmonary trunk.
- The desire to avoid injury to the aortic sinus and aortic valvular apparatus by direct visualization and supra-sinusal implantation.
- The desire to use an autogenous tube created from the autologous arterial wall, thereby avoiding tension, torsion, and distortion of the coronary arterial button, allowing full potential for subsequent growth.
- The desire to minimize dissection around the proximal part of the coronary artery and pulmonary sinuses.
- The desire to place the newly created coronary arterial tube posterior to the pulmonary trunk to avoid extrinsic mechanical compression.

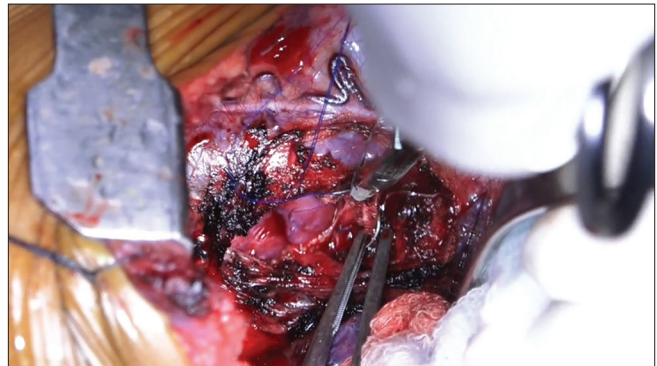
- The desire to minimize pericardial augmentation and maximize the use of autogenous endothelialized arterial wall flaps to avoid thrombosis.
- The desire to apply the procedure in all age groups and in all anatomical variants.

We describe here-in the technical details of reimplantation of the anomalous left coronary artery from the pulmonary trunk in a child aged 18 months using autogenous aortic and pulmonary arterial flaps. The postoperative recovery was uneventful.

SURGICAL TECHNIQUES

Position and surgical approach

Following median sternotomy, the thymus is subtotally excised, taking care not to expose the brachiocephalic vein. The pericardium is harvested using scissors and not cautery to avoid inadvertent cautery-induced ventricular fibrillation. Note the grossly dilated and tortuous coronary arteries. A continuous thrill is palpable at the root of the pulmonary trunk [Video 1].



Video 1: Surgical techniques.

Aortic and venous cannulation, dissection of the ascending aorta and pulmonary trunk

The operation is performed with moderately hypothermic cardiopulmonary bypass at 28°C, angled venous cannulas inserted into the superior and inferior caval veins, and with distal aortic cannulation. The ascending aorta and pulmonary trunk are separated from each other, and the right and left pulmonary arteries are dissected and freed up to their first lobar branch.

Administration of cardioplegia through both the ascending aorta and pulmonary trunk

The aorta and pulmonary trunk are individually cross-clamped and cold hyperkalemic blood cardioplegic solution is infused simultaneously into both vessels at a pressure of 80 mmHg for 3 min to achieve optimal myocardial

protection. This technique avoids run-off of the cardioplegic solution from the orifice of the proximal pulmonary trunk.

Venting of the cardiac chambers

A small right atriotomy is done for decompression of the right heart chambers due to the infused cardioplegic solution. The left heart is vented through the right superior pulmonary vein.

Transection of the pulmonary trunk and creation of the pulmonary arterial flap

The pulmonary trunk is transected between stay sutures just below the bifurcation to fashion a long arterial conduit to augment the bridging aortic flap to the anomalous coronary artery. The orifice of the left coronary artery is located posterolaterally within the left posterior sinus. The proximal part of the left coronary artery is mobilized over a distance of about 1 cm.

Creation of the anteriorly based aortic flap

Next, an anteriorly based, obliquely directed, rectangular flap of the aortic wall is created, approximately 10–15 mm above the sinotubular junction, starting from the posterior aspect toward the left lateral side and continuing to the anterior aspect of the aorta, thereby maintaining anterior continuity of the aortic flap.

Creation of the autologous coronary arterial tube, marking of the neo-aortic site of reimplantation

While selecting the site of re-implantation of the anomalous coronary artery, care is taken not to damage or distort the aortic valve, to implant the anomalous left coronary artery in the appropriate sinus, to elongate the main stem of the artery by combining the obliquely positioned rectangular aortic flap with a vertical pulmonary artery flap so as to obtain a “trapdoor” effect, and avoiding narrowing, flattening, torsion, tension or saccular formation, and to direct the extended main stem of the anomalous artery posterior to the pulmonary trunk in anatomical position without extrinsic compression. The neo-tunneled left coronary artery is implanted above the sinotubular junction to ensure the absence of kinking and external wasting of the left coronary without any tension.

Anastomosis of the coronary artery tube to the neo-aortic window

The isolated segment of the pulmonary trunk containing the left coronary artery at its bottom is approximated to the neo-aortic window. The right inferomedial margin of the pulmonary artery flap is sutured along the posterior lip

of the neo-aortic orifice. The next point of suturing starts on the left inferolateral portion of the pulmonary arterial flap. The two adjacent edges of the inferolateral margin of the pulmonary arterial flaps are sutured with each other, with the left coronary artery orifice at its fulcrum.

Subsequently, the redundant superior edge of the pulmonary arterial flap was folded anteriorly over the left coronary sinus. Finally, the anteriorly based, obliquely directed, small rectangular aortic flap is sutured over the residual flap to obtain a “trapdoor” effect.

The implanted left main coronary artery is elongated to its neo-aortic site. Note the absence of narrowing, flattening, kinking, wasting, tension, torsion, or saccular configuration of the neo-aortic site. The defect within the pulmonary artery was repaired using a pericardial patch.

Short-and long-term results

There were no early or late deaths among the operated patients subjected to this technique. At a median follow-up of 96 months, all patients are in New York Heart Association functional class I/II, with good biventricular function and without the need for any medications. There was a progression of the R wave in leads V1 through V3 on the electrocardiogram. Postoperatively, five patients consented to a stress Thallium investigation and Positron Emission Tomography scan. Left ventricular ejection fraction improved from 30–40% (preoperative) to 50–60% (postoperative). Improvement of mitral regurgitation and abnormal wall motion occurred within 5–6 months in all patients. Echocardiographically, there was no evidence of the right ventricular outflow tract obstruction in any patient.

CONCLUSION

The potential benefits of this modification of the trapdoor technique are excellent operative exposure, use of autogenous, viable tissue capable of further growth, achievement of the anastomosis with correct angling and length, avoidance of injury to the aortic and pulmonary valvular apparatus, and avoidance of obstruction within the right ventricular outflow tract. In addition, the resulting absence of tension, torsion, or traction and the use of viable, endothelialized, autogenous arterial flaps helps to avoid thrombosis.^[21]

Ethical approval

Institutional Review Board approval is not required.

Declaration of patient consent

The authors certify that they have obtained all appropriate patient consent.

Financial support and sponsorship

Nil.

Conflicts of interest

There are no conflicts of interest.

Use of artificial intelligence (AI)-assisted technology for manuscript preparation

The authors confirm that there was no use of artificial intelligence (AI)-assisted technology for assisting in the writing or editing of the manuscript and no images were manipulated using AI.

REFERENCES

- Turley K, Szarnicki RJ, Flachsbarth KD, Richter RC, Popper RW, Tarnoff H. Aortic Implantation is Possible in All Cases of Anomalous Origin of the Left Coronary Artery from the Pulmonary Artery. *Ann Thorac Surg* 1995;60:84-9.
- Vouhé PR, Baillot-Vernant F, Trinquet F, Sidi D, de Geeter B, Khoury W, *et al.* Anomalous Left Coronary Artery from the Pulmonary Artery in Infants. Which Operation? When? *J Thorac Cardiovasc Surg* 1987;94:192-9.
- Dodge-Khatami A, Mavroudis C, Backer CL. Anomalous Origin of the Left Coronary Artery from the Pulmonary Artery: Collective Review of Surgical Therapy. *Ann Thorac Surg* 2002;74:946-55.
- Schwartz ML, Jonas RA, Colan SD. Anomalous Origin of Left Coronary Artery from Pulmonary Artery: Recovery of Left Ventricular Function after Dual Coronary Repair. *J Am Coll Cardiol* 1997;30:547-53.
- Selzman CH, Zimmerman MA, Campbell DN. ALCAPA in an Adult with Preserved Left Ventricular Function. *J Card Surg* 2003;18:25-8.
- Takeuchi S, Imamura H, Katsumoto K, Hayashi I, Katohgi T, Yozu R, *et al.* New Surgical Method for Repair of Anomalous Left Coronary Artery from Pulmonary Artery. *J Thorac Cardiovasc Surg* 1979;78:7-11.
- Alexi-Meskishvili V, Hetzer R, Weng Y, Lange PE, Jin Z, Berger F, *et al.* Anomalous Origin of the Left Coronary Artery from the Pulmonary Artery. Early Results with Direct Aortic Reimplantation. *J Thorac Cardiovasc Surg* 1994;108:354-62.
- Moodie DS, Fyfe D, Gill CC, Cook SA, Lytle BW, Taylor PC, *et al.* Anomalous Origin of the left Coronary Artery from the Pulmonary Artery (Bland-White-Garland Syndrome) in Adult Patients: Long-term Follow-up After Surgery. *Am Heart J* 1983;106:381-8.
- Vigneswaran WT, Campbell DN, Pappas G, Wiggins JW, Wolfe RW, Clarke DR. Evolution of the Management of Anomalous Left Coronary Artery: A New Surgical Approach. *Ann Thorac Surg* 1989;48:560-4.
- Chan RK, Hare DL, Buxton BF. Anomalous Left Main Coronary Artery Arising from the Pulmonary Artery in an Adult: Treatment by Internal Mammmary Artery Grafting. *J Thorac Cardiovasc Surg* 1995;109:393-4.
- Arciniegas E, Farooki ZQ, Hakimi M, Green EW. Management of Anomalous Left Coronary Artery from the Pulmonary Artery. *Circulation* 1980;62:1180-9.
- Backer CL, Stout MJ, Zales VR, Muster AJ, Weigel TJ, Idriss FS, *et al.* Anomalous Origin of the Left Coronary Artery. A Twenty-year Review of Surgical Management. *J Thorac Cardiovasc Surg* 1992;103:1049-57.
- Sese A, Imoto Y. New Technique in the Transfer of an Anomously Originated Left Coronary Artery to the Aorta. *Ann Thorac Surg* 1992;53:527-9.
- Tashiro T, Todo K, Haruta Y, Yasunaga H, Nagata M, Nakamura M. Anomalous Origin of the Left Coronary Artery from the Pulmonary Artery. New Operative Technique. *J Thorac Cardiovasc Surg* 1993;106:718-22.
- Neirotti R, Nijveld A, Ithuralde M, Quaglio M, Seara C, Lubbers L, *et al.* Anomalous Origin of the Left Coronary Artery from the Pulmonary Artery: Repair by Aortic Reimplantation. *Eur J Cardiothorac Surg* 1991;5:368-71.
- Murthy KS, Krishnanaiik S, Mohanty SR, Varghese R, Cherian KM. A New Repair for Anomalous Left Coronary Artery. *Ann Thorac Surg* 2001;71:1384-6.
- Katsumata T, Westaby S. Anomalous Left Coronary Artery from the Pulmonary Artery: A Simple Method for Aortic Implantation with Autogenous Arterial Tissue. *Ann Thorac Surg* 1999;68:1090-1.
- Laks H, Ardehali A, Grant PW, Allada V. Aortic Implantation of Anomalous Left Coronary Artery. An Improved Surgical Approach. *J Thorac Cardiovasc Surg* 1995;109:519-23.
- Kattach H, Anastasiadis K, Jin XY, Pillai R. Two-Conduit Repair for Anomalous Origin of the Left Coronary Artery from the Pulmonary Artery in an Adult. *J Thorac Cardiovasc Surg* 2004;128:641-2.
- Kitamura S, Kawachi K, Nishii T, Taniguchi S, Inoue K, Mizuguchi K, *et al.* Internal Thoracic Artery Grafting for Congenital Coronary Malformations. *Ann Thorac Surg* 1992;53:513-6.
- Chowdhury UK, Kothari SS, Patel CD, Mishra AK, Jagia P, Subramaniam GK, *et al.* An Alternative Technique for Transfer of Anomalous Left Coronary Artery from the Pulmonary Trunk in Children and Adults Using Autogenous Aortic and Pulmonary Arterial Flaps. *Cardiol Young* 2008;18:165-76.

How to cite this article: Chowdhury UK, George N, Goja S. Technical Details of a Novel Surgical Procedure of Anomalous Left Coronary Artery from the Pulmonary Trunk in a Child Using Autogenous Aortic and Pulmonary Arterial Flaps (UKC's Modification): A Video Presentation. *J Card Crit Care TSS*. 2024;8:53-6. doi: 10.25259/JCCC_24S1_UC